

LETTERS TO THE EDITOR

Complex partial seizures provoked by photic stimulation

In patients with known or suspected epileptic seizures, non-specific activation methods such as hyperventilation or intermittent photic stimulation (IPS) are used to provoke epileptic potentials, which may prove the epileptic nature and specify epileptic syndromes. A photoconvulsive reaction with generalised spike wave activity may be provoked by IPS and is almost confined to patients with generalised epilepsy. There are, however, some reports on patients with partial epilepsy and photoconvulsive reaction.¹ We report on two patients with known photoconvulsive reaction, who developed these with focal epileptic discharges consequent to IPS and discuss possible mechanisms.

Patient 1, a 44 year old woman presented with a 33 year history of complex partial seizures starting with behavioural arrest followed by oroalimentary automatisms, which were sometimes followed by secondary generalisation. She was treated with carbamazepine and reported 1-2 seizures a month. Brain MRI failed to disclose any focal abnormality. Except for mild generalised slowing (7.5/s), probably due to or accentuated by carbamazepine, focal slowing (5-4/s) with intermittent spikes showing phase inversion over F₈ was seen in two EEG recordings (average of 1 spike in 7 minutes). During hyperventilation (3 minutes) the number of

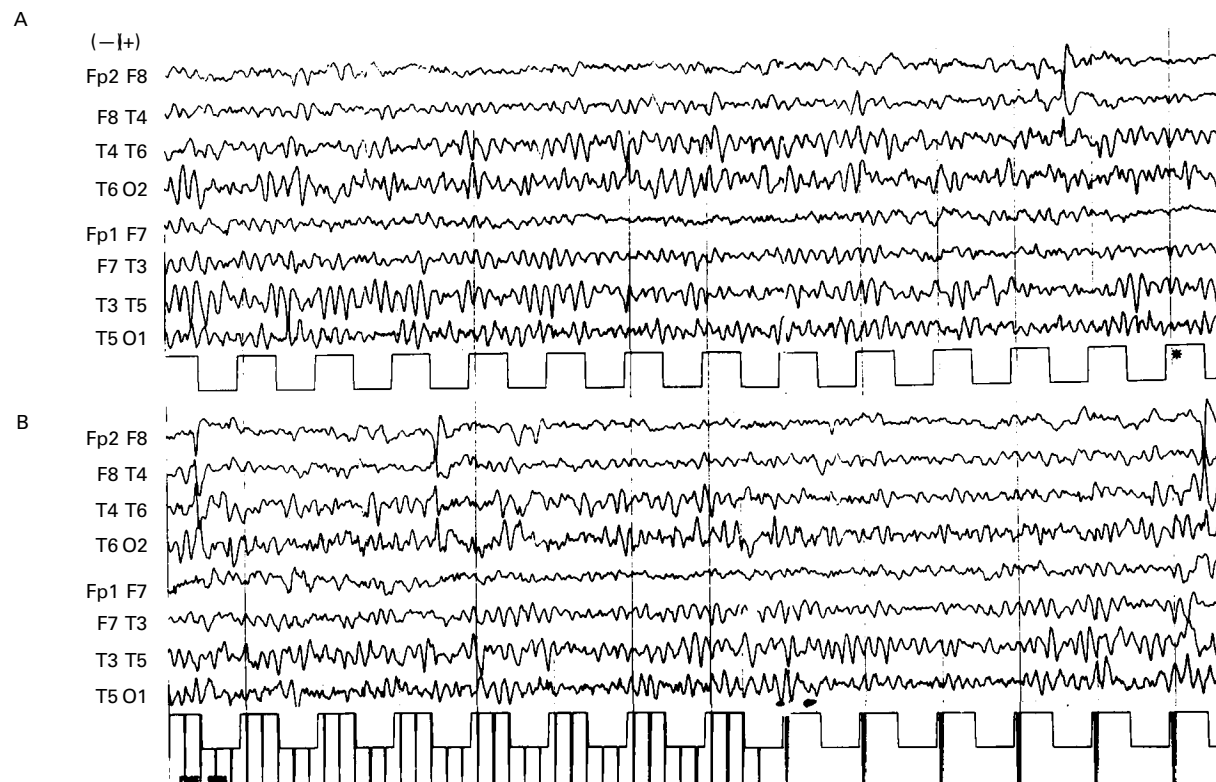
spikes increased to an average of 1 spike in 1 minute. During IPS (started with 1/s duration), the number of single spikes increased to 6 in 3 minutes or 2 per minute (figure). During the second recording, the spike activity in the anterotemporal region finally became rhythmic with subsequent generalisation. This was accompanied by a complex partial seizure typical for this patient (behavioural arrest followed by oroalimentary automatisms) finally running into a generalised tonic-clonic seizure.

Patient 2 was a 19 year old woman who had complex partial seizures with secondary generalisation for 2 years. The seizures started with fear ("indiscribable terror") accompanied by a fearful expression. This was followed by a repetitive ictal speech which was sometimes followed by secondary generalised tonic-clonic seizure. She reported one of these seizures as a consequence of flashing lights in a discotheque and avoided flashing lights since then. She was treated with valproate and reported 4-5 seizures per year. MRI was normal. EEG disclosed focal slowing (4 cps) with phase inversion over T₆, which corresponded to decreased perfusion of the right midtemporal and parietotemporal regions established by HMPAO-SPECT. Intermittent photic stimulation (12/s) evoked a photoconvulsive reaction with bifrontal accentuated generalised spike-wave activity associated with myoclonic eyelid jerks. Independent of photoconvulsive reaction, 8 seconds later on single sharp-wave activity with phase inversion over T₆ occurred consequent to IPS and became rhythmic. This was associated with complex partial seizures starting with fear accompanied by a terrifying fearful expression, which were followed by ictal speech (repetition of single words) finally running into a generalised tonic-clonic seizure

(documented by a simultaneous EEG/Video recording).

Both patients developed complex partial seizures with secondary generalisation resulting from IPS and one of them reported a complex partial seizure provoked by flash-light in a discotheque. To our knowledge, neither complex partial seizures nor activation of temporal epileptic activity consequent to IPS have previously been reported. Specific stimuli like rubbing, cold wind,² or tactile stimuli may evoke spike activity in the contralateral cerebral regions and provoke partial seizures. Even patients with myoclonic epilepsy may develop contralateral spikes after electrical peripheral nerve stimulation. In all these patients, spike potentials were evoked in primary cortical representation areas of the respective stimuli. Our patients showed provocation of anterotemporal (F₈, patient 1) and posterotemporal (T₆, patient 2) epileptic activity resulting from IPS, which may have been adjacent to the visual cortex in patient 2 but was distinctly apart from the primary visual cortex in patient 1. Complex partial seizure symptomatology in the first patient included oroalimentary automatisms, indicating a seizure origin in the amygdalo-hippocampal complex. Visual hallucinations, which are likely with epileptic discharges in the visual cortex or visual association areas, however, were missed. This indicates that provoked complex partial seizures during IPS in our patients occurred without epileptic activity in the visual cortex. Temporal epileptic activity as a consequence of IPS was probably mediated via occipitotemporal connections such as the fasciculus longitudinalis inferior.

Provocation of sharp waves with phase inversion over F₈ and the occurrence of a photoconvulsive reaction in patient 2 raises the question whether both phenomena were



Spike activity during EEG registration in patient 1: (A) without provocation; (B) while IPS.

interrelated. Similar constellations were previously reported in individual patients with photoconvulsive reaction who had partial epilepsy and occipital epileptic focus.³ Cortical and subcortical recordings in monkeys during IPS showed paroxysmal discharges predominantly in prerolandic areas, which were followed by bursts in the pontine and mesencephalic reticular formation and, finally, by generalised discharges.⁴ These findings have been interpreted in favour of a cortical origin of the photoconvulsive reaction, which is supported by the studies of Ricci *et al* using neuromagnetic methods in humans with photoconvulsive reaction to identify the location of the photoconvulsive reaction generator: They found a regional sensitivity involving frontal, occipital, and temporal areas, but the cortical excitability was extremely unstable, which was attributed to a deficient GABA-ergic system. This suggests that photoconvulsive reaction is a generalised phenomenon and not due to polyfocal generation. The occurrence of focal epileptic discharges associated with focal seizures and secondary generalisation in patient 2 does not indicate a relation between focal epileptic discharges and the photoconvulsive reaction as the second appeared in only one of the patients.

S SEDDIGH
F THÖMKE
TH VOGT

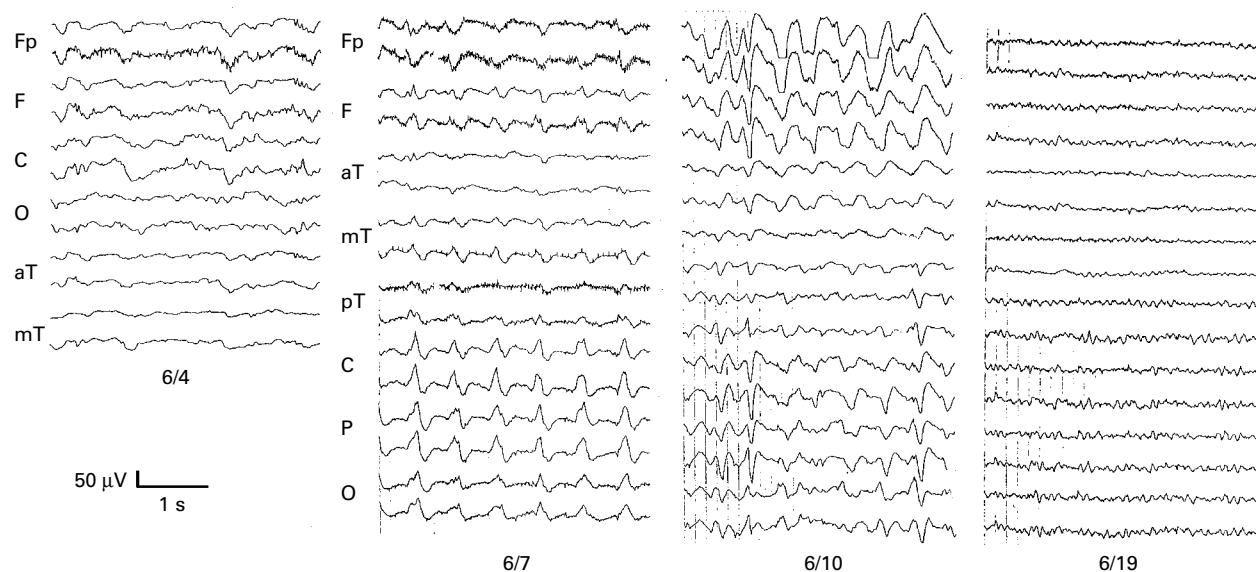
Department of Neurology, University of Mainz,
Germany

Correspondence to: Correspondence to: Dr Susann Seddigh, Neurologische Klinik und Poliklinik, Langenbeckstrasse 1, D 55101 Mainz, Germany.

Creutzfeldt-Jakob-like syndrome related to lithium

Drugs (other than lithium)	Authors	Age/sex	SL	PD
None	Smith <i>et al</i> ¹	69/F	T	(+)
None	Primavera <i>et al</i> ²	59/F	T	(+)
None	Primavera <i>et al</i> ²	56/M	NT	(+)
None	Takahashi <i>et al</i> ³	67/F	T	(+)
Levodopa	Broussolle <i>et al</i> ⁴	70/F	NA	(+)
Lorazepam	Casanova <i>et al</i> ⁴	67/M	NT	(+)
Nortriptyline	Finelli ⁵	63/M	NT	(-)
Phenobarbitone, levomepromazine	This case	65/F	T	(+)
Madpar*, others	Smith <i>et al</i> ¹	72/F	NT	(+)
Bromazepam, trihexyphenidyle, others	Masmoudi <i>et al</i> ⁶	66/F	NT	Pseudoperiodic

Li=lithium, SL=serum lithium concentration; PD=periodic discharge, T=toxic, NT=not toxic, NA=not assessed, Madpar*=levodopa/benserazide.



EEG on 4, 7, 10, and 19 June. It shows PSD on 7 June. The amplitude of the PSD is 150–200 μ V and the frequency is 1.5–2 Hz.

Telephone 0049 6131 172226; fax 0049 6131 173271.

- 1 Kasteleijn-Nolst Trenite DGA. Photosensitivity in epilepsy. Electrophysiological and clinical correlates. *Acta Neurol Scand* 1989;80(suppl):125.
- 2 Takahashi T. Activation methods. In: Niedermeyer E, Lopes Da Silva I, eds. *Electroencephalography*. Baltimore-Munich: Urban und Schwarzenberger, 1993:241–61.
- 3 Wolf P, Groosess R. Relation of photosensitivity to epileptic syndroms. *J Neurol Neurosurg Psychiatry* 1986;49:1386–91.
- 4 Silva-Barrat C, Menini Ch, Bryere P, *et al*. Multitertiary activity analysis of cortical and subcortical structures in paroxysmal discharges and grand mal seizures in photosensitive baboons. *Electroencephalogr Clin Neurophysiol* 1986;64:455–68.
- 5 Ricci GB, Chapman RM, Erne SN, *et al*. Neuromagnetic topography of photoconvulsive response in man. *Electroencephalogr Clin Neurophysiol* 1990;75:1–12.

Creutzfeldt-Jakob-like syndrome induced by lithium, levomepromazine, and phenobarbitone

Creutzfeldt-Jakob-like syndrome was first reported by Smith and Kocen¹ in 1988. Its symptoms resemble Creutzfeldt-Jakob disease but it is induced by drugs, particularly lithium, and most patients recover without sequel after discontinuation of drugs. It also displays a characteristic EEG similar to Creutzfeldt-Jakob disease, but this returns to normal when the patient recovers.

There have been some case reports of Creutzfeldt-Jakob-like syndrome after that of Smith *et al* (table), but no paper seems to

have described the detailed course of EEG changes. This paper presents a case of Creutzfeldt-Jakob-like syndrome possibly induced by lithium, levomepromazine, and phenobarbitone, in which we succeeded in recording the course of EEG changes.

A 65 year old woman was admitted to a hospital with coma and myoclonus. She had a history of manic and depressive disease for 8 years and had been treated with 200 mg lithium carbonate, 25 mg chlorpromazine, and 10 mg levomepromazine daily. Her first symptom was forgetfulness from 20 May, then she complained of appetite loss from 27 May, diarrhoea from 1 June, myoclonus from 3 June, and gait disturbance from 4 June. At the same time she complained of visual disturbance. Gradually her conscious level declined. When she was admitted to the hospital on 4 June, she had convulsions. At that time, she was injected with 200 mg phenobarbitone intramuscularly and this was continued for 2 more days at the same dose. Physical examination disclosed no abnormality. Neurologically there was general hypotonus and hyporeflexia without Babinski's sign. Serum glutamic oxaloacetic transaminase, glutamic pyruvic transaminase alkaline phosphatase, and creatine kinase was increased slightly, and serum ammonia was 64 μ mol/l (normal range 30–59 μ mol/l). Plasma sodium and potassium concentrations were normal. Her creatinine clearance was 46 ml/min and thyroid function was normal. Examination of CSF gave normal results. Chest radiography, brain CT, and brain MRI showed no abnormality. ECG showed T wave inversion from V1 to V3. The EEG showed slow basic activity but no periodic discharge on 4 June, but showed PSD on 7 June (figure).

Its periodicity decreased on 10 June and had returned to her previous EEG on 19 June. Her ECG had also returned to normal by 14 June. Her myoclonus disappeared on 6 June, and her conscious level gradually improved from 9 June; she could open her eyes on 10 June, then could answer our questions regarding place and time and could walk without help from 13 June. She was discharged on 25 June fully recovered.

She was diagnosed as having Creutzfeldt-Jakob-like syndrome induced by lithium,

chlorpromazine, levomepromazine, and phenobarbitone. Her CSF lithium concentration was 0.82 mmol/l on 4 June. According to Taguchi *et al.*,² lithium concentration in CSF is about one fourth of the serum concentration after taking lithium for more than 1 week, and it is said that a serum lithium concentration is toxic above 1.5 mmol/l,³ so her serum concentration is likely to be high enough to be toxic. Her symptoms such as forgetfulness, diarrhoea, coma, myoclonus, and visual disturbance were all compatible with lithium intoxication. The cause of her high lithium concentration was clear with the discovery that she took three times as much as prescribed when she could not sleep well. Periodic EEG emerged 3 days after all the drugs were discontinued and was displayed for about 3 days. There are some case reports of Creutzfeldt-Jakob-like syndrome induced by chlorpromazine and levomepromazine, but there are apparently no reports of its induction by phenobarbitone. We could not identify the role of phenobarbitone injected from 4 to 6 June, but it was possible it might have some part in the induction of PSD, and her hypotonicity and hyporeflexia are uncommon compared with previous reports.⁴⁻⁶ In conclusion, this drug induced Creutzfeldt-Jakob-like syndrome showed us the importance of taking a drug history, as previously pointed out by Smith *et al.*

HIDEYUKI KIKYO

Shemaron 201, 3-12-28 Negishi, Taito-ku,
Tokyo 110, Japan

TETSUO FURUKAWA

1-5-45 Yushima Bunkyo-ku, Tokyo 113, Japan

Correspondence to: Dr Hideyuki Kikyo, Department of Neurology, Tokyo Medical and Dental University, Tokyo, Japan. email: kikyo@m.u-tokyo.ac.jp

- Smith SJM, Kocan RS. A Creutzfeldt-Jakob like syndrome due to lithium toxicity. *J Neurol Neurosurg Psychiatry* 1988;51:120-3
- Taguchi K, Watanabe S, Ebara T, *et al.* Lithium distribution between cerebrospinal fluid and serum of affective psychotic patients treated with lithium carbonate and its clinical response. *Medicine and Biology* 1973;86:333-6
- Van Kempen GMJ. Lithium. *Handbook of clinical neurology*. Vol 20. Amsterdam: Elsevier, 1994.
- Finelli PF. Drug-induced Creutzfeldt-Jakob like syndrome. *J Psychiatr Neurosci* 1992;17:103-5.
- Casanova B, de Entrambasaguas M, Perla C, *et al.* Lithium-induced Creutzfeldt-Jakob syndrome. *Clin Neuropharmacol* 1996;19:356-9.
- Masmoudi K, Rosa A, Canaple S, *et al.* Pseudo-Creutzfeldt-Jakob syndrome with long-term lithium use. *Therapie* 1996;51:688-90.
- Primavera A, Brusa G, Poeta MG. A Creutzfeldt-Jakob like syndrome due to lithium toxicity. *J Neurol Neurosurg Psychiatry* 1989;52:423.
- Takahashi M, Hashimoto S, Suenaga T, *et al.* Creutzfeldt-Jakob-like syndrome due to lithium intoxication—a case report. *Clin Neurol* 1997;37:338-40.
- Broussolle E, Setiey A, Moene Y, *et al.* Reversible Creutzfeldt-Jakob like syndrome induced by lithium plus levodopa treatment. *J Neurol, Neurosurg Psychiatry* 1989;52:686-687.

Central nervous system involvement in a novel connexin 32 mutation affecting identical twins

Connexin 32 (Cx32) is a gap junction protein expressed in the peripheral nervous system (PNS), central nervous system (CNS), and in many other tissues.¹ Mutations in the Cx32 gene are associated with X-linked Charcot-Marie-Tooth disease (CMTX), and account for about 10% of the patients with hereditary motor and sensory neuropathy (HMSN).

At least 130 different mutations have been reported in the Cx32 gene causing peripheral neuropathy. Classically, distal weakness and atrophy initially involving the lower limbs, as well as sensory abnormalities, depressed tendon reflexes, and pes cavus are usually found in affected males by the second decade, whereas in carrier females clinical manifestations, if present, are in most instances milder than in affected males. Nerve conduction studies in affected males are usually, but not always, suggestive of a demyelinating process, although they are not quite as slow as in patients with CMT1A. In females, conduction velocities (CVs) may be in the normal range or only mildly reduced, as seen in axonal neuropathies.

We describe a new Cx32 point mutation (Ala³⁹ to Val) in genetically established identical twins with similar CMT phenotypes and extensor plantar reflexes.

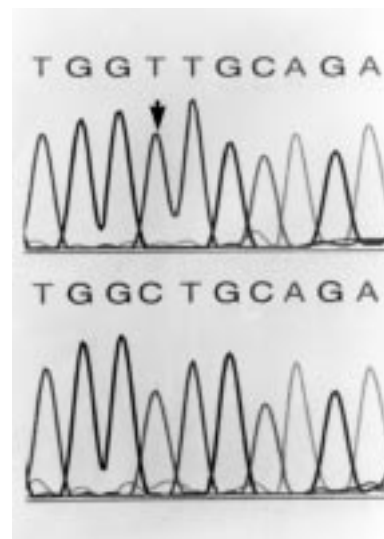
The probands were first seen at the age of 20. Their principal complaint was cramps in the legs, "going over" on the ankles, and mild weakness in the hands. On examination, Twin 1 could not stand on his heels and had a mild intrinsic hand muscle weakness. There was a mild distal atrophy in both upper and lower limbs. Pinprick and tactile sensations were diminished up to the knees and vibration was impaired distally in the lower limbs. Tendon reflexes were absent or depressed, but both plantar responses were extensor. His median, ulnar, and peroneal motor CVs were 33.0 m/s, 33.0 m/s, and 31.0 m/s, respectively, and the distal amplitudes were 0.7 mV, 5.0 mV, and 3.3 mV. The sensory potentials were all absent. Twin 2 had identical clinical manifestations, except that the left plantar reflex was flexor whereas the right was clearly extensor. His motor CVs and amplitudes of the same nerves described above were 32.0 m/s and 1.7 mV, 34.0 m/s and 6.0 mV, and 33.0 m/s and 4.0 mV, respectively. No sensory response was obtained. Their mother had minimal neuropathic features and both plantar reflexes were extensor. Her median and peroneal motor CVs were 43.0 m/s and 37.0 m/s, and the median sensory CV was 40.0 m/s. Their sister and the mother's brother were clinically and electrophysiologically normal. The maternal grandfather was not examined, but had a long history of a slowly progressive neuropathy.

The presence of the 17p11.2-p12 duplication was excluded with fluorescent quantitative polymerase chain reaction with five microsatellite markers contained within the involved segment.

Sequencing Cx32 with the ABITM Dye Primer Cycle Sequencing Ready Reaction detected a C¹⁹⁹ to T transition (figure) at amino acid 39 causing an alanine to valine substitution in the first extracellular loop. This mutation abolishes a restriction site for the enzyme *Bbv* I and on screening 200 control chromosomes and the father's DNA, no mutation was found. The mother was shown to harbour the mutation.

The monozygosity status of the twins was confirmed by the demonstration of the same alleles at each of the 13 highly polymorphic microsatellite markers tested. The possibility of this occurring by chance is >0.01%.

CMTX is now recognised as a frequent cause of HMSN.¹ Mutations have been detected in all domains of the protein and are postulated to be either non-functional or exert a dominant-negative effect. The clinical manifestations detected in this family with a novel point mutation leading to an Ala³⁹ to



Sense electropherogram of a segment of Cx32 exon 2 showing the C to T mutation at base pair 39 (upper trace) and the corresponding control segment (lower trace).

Val amino acid substitution are clearly on the mild side of the classic CMT phenotype spectrum. This amino acid is conserved in other species, not found in 200 control chromosomes and segregates with the disease.

A second notable feature in this family is the presence of extensor plantar responses in all three people shown to carry the mutation. Involvement of the CNS in patients with Cx32 mutations have been demonstrated by slowing of the central conduction time in their brain stem auditory evoked potentials,² but clinical manifestations secondary to central dysfunction does not seem to be a frequent finding. Paulson *et al.* reported a patient who developed dysarthria and incoordination after high altitude skiing. His MRI showed confluent, symmetric, white matter changes. Another member of the family carrying the mutation had normal MRI⁴ and other non-related patients with the same mutation did not show any clinical signs of CNS involvement, raising the possibility of a casual association. Bell *et al.* presented a family with a mutation on code 93 whose clinical manifestations included tremor, brisk reflexes, and spasticity. On MRI there was atrophy of the cerebral cortex and cerebellum. The presence of a Babinski's sign in our family strongly suggests that in this novel mutation there is involvement of the corticospinal tract. Unfortunately no imaging or evoked potential studies were possible.

Cx32 is a gap junction protein expressed in the paranodal region and Schmidt-Lanterman incisures in the PNS, and in cell bodies and oligodendrocytes processes in the CNS. Why mutations in Cx32 usually lead only to PNS dysfunction is still an open question. Presumably, there is a unique relation between Cx32 and the structural organisation or metabolic requirements of the PNS. Another possibility is that other connexin proteins might compensate for Cx32 dysfunction in the CNS and other tissues, but not in the PNS.

Although the clinical manifestations are extremely similar in most of the Cx32 neuropathies suggesting that different mutations do not cause different phenotypes, different degrees of severity and the presence of unusual signs, like the one we present here,

have already been described to occur with some mutations.

There are only two previous reports relating to three pairs of identical twins with CMT and known genetic defects. In the two pairs with the 17p11.2 duplication there was remarkable clinical variability.⁶ We have also seen a pair of identical twins with a P0 mutation in whom there was marked variability in early ages (unpublished data). Apart from the asymmetry of toe responses in one of the probands, the genetically identical twins described here are phenotypically very similar, suggesting that the expression of this mutation was not influenced by other non-genetic factors.

Codon 39 seems to be of particular importance to Cx32 protein function as changing of the wild type amino acid has caused CNS dysfunction in addition to the peripheral neuropathy. Moreover its expression does not seem to depend on non-genetic factors, as might be expected in a hemizygous condition.

WMJr was supported by grants from CAPES, FAPESP, and FAPPA (Brazil).

W MARQUES JR
M G SWEENEY
N W WOOD

University Department of Clinical Neurology,
Institute of Neurology, Queen Square, London, UK

S J WROE
Department of Clinical Neurology,
Ipswich Hospital NHS Trust, Ipswich, UK

W MARQUES
Department of Neurology,
School of Medicine of Ribeirão Preto, Brazil

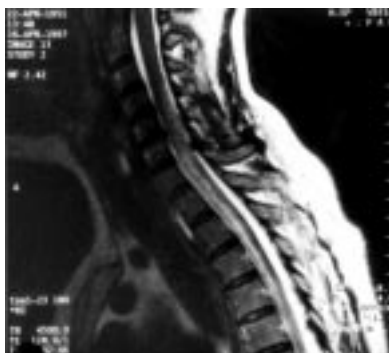
Correspondence to: Dr Nicholas Wood, Institute of Neurology, Queen Square, London WC1N 3BG, UK. Telephone 0044 171 837 3611 extn 4255; fax 0044 171 278 5616.

- 1 Bone LJ, Deschênes SM, Balice-Gordon RJ, et al. Connexin 32 and X-linked Charcot-Marie-Tooth disease. *Neurobiology of Disease* 1997;4:221–30.
- 2 Nicholson G, Corbett A. Slowing of central conduction in X-linked Charcot-Marie-Tooth neuropathy shown by brain stem auditory evoked responses. *J Neurol Neurosurg Psychiatry* 1996; 61:43–6.
- 3 Paulson H, Deschênes S, Scherer S, et al. CNS white matter abnormalities in a patient with X-linked Charcot-Marie-Tooth disease (CMTX). *Am J Hum Genet* 1994;55:497.
- 4 Latour P, Fabreguette A, Ressay C, et al. New mutations in the X-linked form of Charcot-Marie-Tooth disease. *Eur Neurol* 1997;37:38–42.
- 5 Bell C, Willison H, Clark C, et al. CNS abnormalities in a family with a connexin 32 mutation and peripheral neuropathy. *Eur J Hum Genet* 1996;4(suppl 1):136
- 6 Garcia CA, Malamut RE, England JD, et al. Clinical variability in two pairs of identical twins with Charcot-Marie-Tooth disease type 1A duplication. *Neurology* 1995;45:2090–3.

Isolated ischaemia of the spinal cord due to bilateral vertebral artery dissection

Clinical features in vertebral artery dissection are rarely associated with an ischaemic lesion of the spinal cord.¹ The few cases related and studied with MRI strictly involve the cervical cord.^{2–4} We add another patient with spontaneous bilateral vertebral artery dissection in whom the particularity was an isolated extensive ischaemia of the spinal cord from C4 to T5 vertebral levels.

A previously healthy 45 year old woman had paresthesiae of the right ankle lasting a few days. Ten days later, she had a right sided scapulothoracic pain and suddenly developed



Sagittal T2 weighted MRI of the cervicodorsal cord: high linear signal extending from C4 to T5 vertebral levels.

a predominantly right sided tetraparesia and urinary retention. There was no history of neck trauma. Cranial nerve examination was normal. There was a right sided hemiplegia and a moderate left sided hemiparesis. Deep tendon reflexes were normal, right plantar response was extensor. There were bilateral spinothalamic problems below T4 with loss of touch sense in the right leg. Thus the examination was consistent with atypical, right cervical Brown-Séquard's syndrome.

Biological investigations were normal. CSF protein was 0.34 g/l, glucose 2.54 mmol/l (2.10–4.20 mmol/l). There were 7 white cells and 25 red cells/mm³.

There were no oligoclonal bands. The ECG was normal. There was no aortic dissection shown on CT or MRI. Visual evoked potentials were normal. Somatosensory evoked potentials were abnormal for the right lower limb at the cervical level. A sagittal T2 weighted MRI showed linear cord high signal from C4 to T5 vertebral levels consistent with an ischaemic lesion (figure). On corresponding axial cuts, this was shown to involve the region of the anterior horns at cervical level and to prevail on the right half of the spinal cord at dorsal level. MRI of the cerebellum and brain stem was normal. Cerebral angiography showed an irregular stenosis of the right and left cervical vertebral artery typical of a dissection. The patient was treated with oral anticoagulants. One year later, the sequelae were a spastic paraparesia with right sided central pain and mild urinary retention. MRI and MRA showed the resolution of the cord signal and normal right and left vertebral artery.

The cervical cord is mainly supplied by radicular arteries rising from the vertebral artery. Thus, vertebral artery dissection can lead to an ischaemia limited to the cervical cord. Extensive ischaemia to the dorsal cord (T5) is uncommon. Our results suggest that this area is sometimes supplied from the vertebral artery. Some authors state that this region could be a critical zone and its vascularisation could be provided from the arterial cervical cord region.⁵ The bilateral ischaemic lesions extending through several cervical and dorsal segments are in favour of watershed infarcts caused by hypoperfusion due to bilateral vertebral artery dissection.

P GARNIER
D MICHEL
R PEYRON
O BEAUCHET
Department of Neurology

F LE BRAS
F G BARRAL
Department of Neuroradiology, University Hospital
Saint-Etienne, 42055 Saint -Etienne, France

Correspondence to: Dr D Michel, Service de Neurologie, Hôpital de Bellevue, 42055 Saint-Etienne, Cedex 2, France.

- 1 Goldsmith P, Rowe D, Jäger R, et al. Focal vertebral artery dissection causing Brown-Séquard's syndrome. *J Neurol Neurosurg Psychiatry* 1998;64:415–16.
- 2 Gutowski NJ, Murphy RP, Beale DJ. Unilateral upper cervical posterior spinal artery syndrome following sneezing. *J Neurol Neurosurg Psychiatry* 1992;55:841–3.
- 3 Bergqvist CAG, Goldberg HI, Thorarensen O, et al. Posterior cervical spinal cord infarction following vertebral artery dissection. *Neurology* 1997;48:1112–5.
- 4 Hundsberger T, Thömke F, Hopf HC, et al. Symmetrical infarction of the cervical spinal cord due to spontaneous bilateral vertebral artery dissection. *Stroke* 1998;29:1742.
- 5 Masson C. Les accidents ischémiques médullaires. *Presse Med* 1994;23:1723–8.

Autonomic dysfunction and orthostatic hypotension caused by vitamin B12 deficiency

Orthostatic hypotension sometimes is a reversible neurological complication of vitamin B12 deficiency.^{1,2} Eisenhofer detected deficient sympathetic catecholamine release in insulin tolerance testing,² but the mechanism of orthostatic hypotension in vitamin B12 deficiency remains unclear. We report a patient with vitamin B12 deficiency and reversible orthostatic hypotension, and discuss the mechanism of this symptom.

A 77 year old man admitted to our hospital had had unstable gait and urinary urgency for 6 months, clumsiness of the hands and tingling sensations in the legs for 3 months, and, for a month, occasional dizziness on standing. The dizziness was mild without any attack of syncope. He had no other symptoms or signs of autonomic dysfunction but impotence and erectile failure were noted 10 years before the onset of neurological symptoms. He had not taken any medicine which would affect the autonomic nervous system. He did not have a habit of drinking.

Physical examination on admission detected no signs of anaemia, heart failure, or dehydration. Neurological examination showed dysaesthesia and decreased sensation of all modalities in distal parts of all the limbs. Deep tendon reflex was absent in the lower limbs, and Babinski's sign was positive bilaterally. Mild limb ataxia was seen in the four limbs, and Romberg's test was positive.

Haematological studies disclosed mild macrocytic hyperchromic anaemia (haemoglobin 14.0 g/dl, mean corpuscular volume 104 fl, mean corpuscular haemoglobin concentration 35.2 pg), with a few (3%) hypersegmented polymorphonuclear cells. His serum vitamin B12 concentration was markedly decreased (38 pg/ml; normal 249–938 pg/ml). Intrinsic factor and parietal cell antibodies were positive in the serum. Echo cardiography showed no evidence of heart failure. In a study of peripheral nerve conduction, amplitudes of sensory nerve action potentials were slightly decreased in the lower limbs. The somatosensory evoked potential on median nerve stimulation showed a moderately prolonged central conduction time. Urodynamics studies disclosed uninhibited neurogenic bladder with detrusor sphincter dyssynergia.

Results of the autonomic nervous system tests before and 6 months after treatment are given in the table. When the patient was tilted up to 60 degrees, he experienced dizziness and a significant fall in systolic blood pressure

over 30 mm Hg with normal heart rate response. His serum noradrenalin concentration was reduced at rest, and its increase after tilting up was minimal. Sudomotor function was evaluated by sympathetic skin response (SSR)³ and local sweat response to acetylcholine (ACh).⁴

Before treatment, the SSR amplitude was decreased, and the number and area of sweat droplets were decreased in responses to intradermal ACh injection.

The myelinated fibre density of biopsied sural nerve was 5927/mm². Some thin myelinated fibres were present, as were a few myelin ovoids. Examination of the teased fibres showed evidence of demyelination (about 20%) and axonal degeneration (about 10%). Electron microscopy showed a normal unmyelinated fibre density (30 945 /mm²). Collagen pockets (15 000 /mm²), and denervated Schwann cell subunits (12 000 /mm²) were present, but their densities were within the normal range for his age.⁵

A highly sensitive acetylcholinesterase (AChE) histochemical test (modified Tago's method)⁶ of the sural nerve detected a slightly reduced density of sudomotor sympathetic unmyelinated fibres (3500 /mm²; normal 3700–6500 /mm²).

Daily intramuscularly administered 1 mg vitamin B12 for a week then 1 mg once a month increased its serum concentration rapidly to normal, resulting in the gradual amelioration of orthostatic dizziness, and his neurological symptoms except for erectile failure, after a month.

The abnormalities seen in the autonomic nervous system tests also disappeared when vitamin B12 was given for 6 months (table). The lesion of the baroreflex responsible for his orthostatic hypotension is considered to be in the efferent pathway because of the preserved heart rate response in head up tilt test. The low serum noradrenalin concentration in particular can be explained by disturbance of the sympathetic postganglionic fibres. These findings are supported by the decreased SSR amplitude and the reduced local sweat response to ACh. By contrast, the density of the unmyelinated fibres and AChE positive fibres were relatively well preserved when his age was considered. Furthermore, there was the rapid recovery of serum noradrenalin concentration, the SSR size, and the sweat response to ACh after giving the vitamin B12 supplement. These results suggest dysfunction of the sympathetic postganglionic fibres without marked morphological change, although we cannot exclude the possibility that sympathetic neurons in the brainstem or spi-

nal cord induce the dysfunction of postganglionic fibres by a trans-synaptic effect.^{7,8} Vitamin B12 is related to the methylation reaction regulated by S-adenosylhomocystine and S-adenosylmethionine.⁹ This reaction has a crucial role in the myelin formation associated with neurological deficits in patients with vitamin B12 deficiency. Dysfunction in unmyelinated sympathetic neurons, however, has not been shown. Our findings suggest that vitamin B12 is required for the physiological function of sympathetic postganglionic fibres.

SHUTA TORU
TAKANORI YOKOTA
AKIRA INABA
MASANAGA YAMAWAKI
MASAHIITO YAMADA
HIDEHIRO MIZUSAWA

Department of Neurology, Tokyo Medical and Dental University, Tokyo, Japan

MICHIYUKI HAYASHI
Department of Neurology, Tokyo Metropolitan
Neurological Hospital, Tokyo Japan

Correspondence to: Dr T Yokota, Department of Neurology, Tokyo Medical and Dental University, 1-5-45 Yoshima, Bunkyo-Ku, Tokyo 113-8519, Japan. Fax 0081-3-5803-0169.

- 1 Kalbfleish JM, Woods AH. Orthostatic hypotension associated with pernicious anemia: report of a case with complete recovery following vitamin B12 therapy. *JAMA* 1962;182:198–200.
- 2 Eisenhofer G, Lambie DG, Johnson RH, et al. Deficient catecholamine release as the basis of orthostatic hypotension in pernicious anemia. *J Neurol Neurosurg Psychiatry* 1982;45:1053–5.
- 3 Yokota T, Matunaga T, Okiyama R, et al. Sympathetic skin response in patients with multiple sclerosis compared with spinal cord transection and normal control. *Brain* 1991; 114:1381–94.
- 4 Kennedy WR, Sakuta M, Sutherland D, et al. Quantification of the sweating deficiency in diabetes mellitus. *Ann Neurol* 1984;15:482–8.
- 5 Kanda T, Tsukagoshi H, Oda M, et al. Morphological changes in unmyelinated nerve fibers in the sural nerve with age. *Brain* 1991;114:585–96.
- 6 Hayashi M, Yokota T, Miyamoto K, et al. Acetylcholinesterase histochemistry by Tago's method in human sural nerves. *Autonomic Nervous System (Tokyo)* 1990;27:459–64.
- 7 Cohen J, Low P, Fealy R, et al. Somatic and autonomic function in progressive autonomic failure and multiple system atrophy. *Ann Neurol* 1987;22:692–9.
- 8 Mathias CJ, Christensen NJ, Corbeett JL, et al. Plasma catecholamine during paroxysmal neurogenic hypertension in quadriplegic man. *Circ Res* 1976;39:204–8.
- 9 Metz J. Cobalamin deficiency and the pathogenesis of nervous system disease. *Annu Rev Nutr* 1992;12:59–79.

Results of autonomic nervous system tests before and after vitamin B12 treatment

		Before treatment	After treatment	Age matched normal control
Head-up tilting test	Systolic blood pressure (mm Hg)			
	Supine	104	106	112 - 135
	5 min after tilting	71	93	118 - 140
Heart rate (/min)	15 min after tilting	76	106	
	Supine	58	66	59 - 83
	5 min after tilting	70	73	65 - 95
Noradrenaline (pg/ml)	15 min after tilting	73	76	
	Supine	94	177	128 - 512
	5 min after tilting	129	286	258 - 752
Sympathetic skin response	Amplitude (mV)			
	L palm	0.33	1.9	1.2 - 15.3
	R palm	0.39	1.0	
	L Sole	0.67	1.9	0.71 - 8.8
	R Sole	0.61	1.2	
Local sweat response to acetylcholine	Number of sweat droplets (/cm ²)	24	69	42 - 72
	Total area of sweat droplets (mm ² /cm ²)	0.27	2.86	0.75 - 11.5

CORRESPONDENCE

Sandifer's syndrome and gastro-oesophageal reflux disease

Perkin and Murray-Lyon's *Neurology and the gastrointestinal system* reviews gastrointestinal disorders with neurological features.¹ The authors do not mention Sandifer's syndrome, a disorder of the upper gastrointestinal tract with neurological manifestations occurring in children and adolescents. Sandifer's syndrome is the association of gastro-oesophageal reflux disease with spastic torticollis and dystonic body movements. Nodding and rotation of the head, neck extension, gurgling sounds, writhing movements of the limbs, and severe hypotonia have been reported.^{2–4} It is hypothesised that such positionings provide relief from discomfort caused by acid reflux.² A causal relation between gastro-oesophageal reflux disease and the neurological manifestations of Sandifer's syndrome is supported by the resolution of the manifestations on successful treatment of gastro-oesophageal reflux disease.^{2–7} The clinical manifestations almost invariably arouse the suspicion of neurological disease and lead to unnecessary investigative procedures.⁴ The intermittent occurrence of torticollis with alternating directions, normal sternocleidomastoid muscles, and normal cervical radiographic findings make Sandifer's syndrome a probable diagnosis and necessitate upper gastrointestinal studies.⁶

Most patients have no other abnormalities. Sandifer's syndrome is manifested by a relatively large number of patients with brain damage or metabolic disorders and is often interpreted as a feature of their basic disorder.⁴ A high prevalence of Sandifer's syndrome was reported in the Brachman-de Lange syndrome.⁷ These findings may simply reflect the high prevalence of gastro-oesophageal reflux disease among brain damaged children rather than a primary feature of these disorders.⁸

Early recognition and treatment of gastro-oesophageal reflux disease in patients with Sandifer's syndrome enhances the success of medical management, is curative for patients with no other disorders, and contributes to improved quality of life for patients with brain damage.^{4,6,8}

DEMETRIOS S THEODOROPOULOS

RICHARD F LOCKEY

Division of Allergy and Immunology

H WORTH BOYCE, JR

Center for Swallowing Disorders, Department of Internal Medicine, University of South Florida College of Medicine, and James A Haley Veterans Hospital, 13000 Bruce B Downs Boulevard, Tampa, Florida 33612, USA

Correspondence to: Dr DS Theodoropoulos, Division of Allergy and Immunology, Department of Internal Medicine, University of South Florida College of Medicine and James A. Haley Veterans Hospital (111D), 13000 Bruce B. Downs Boulevard, Tampa, FL 33612, USA.

- 1 Perkin GD, Murray-Lyon I. Neurology and the gastrointestinal system. *J Neurol Neurosurg Psychiatry* 1998;65:291–300.
- 2 Kinsbourne M. Hiatus hernia with contortions of the neck. *Lancet* 1964;i:1058–61.
- 3 Sutcliffe J. Torsion spasm and abnormal postures in children with hiatus hernia Sandifer's syndrome. *Prog Pediatr Radiol* 1969;2:190–7.

- 4 Mandel H, Tirosh E, Berant M. Sandifer syndrome reconsidered. *Acta Paediatr Scand* 1989;78:797-9.
- 5 Gellis SS, Feingold M. Syndrome of hiatus hernia with torsion spasms and abnormal posturing. *Am J Dis Child* 1971;121:43-54.
- 6 Murphy WJ, Gellis SS. Torticolis with hiatus hernia in infancy. *Am J Dis Child* 1977;131:564-5.
- 7 Sommer A. Occurrence of the Sandifer complex in the Brachmann-de Lange syndrome. *Am J Med Genet* 1993;47:1026-8.
- 8 Sondheimer J, Morris BA. Gastroesophageal reflux among severely retarded children. *J Pediatr* 1979;94:710-14.

Is inherited thrombophilia a risk factor for arterial stroke?

The paper of Ganesan *et al*¹ adds the factor V Leiden mutation to the list of inherited thrombophilias which has not been shown to be significantly increased in consecutive series of children and young adults with arterial stroke.²⁻⁴ In their commentary on this paper, Brown and Bevan⁵ admit ignorance as to whether the finding of inherited thrombophilia in a patient with stroke indicates an increased risk of recurrent stroke but nevertheless recommend consideration of lifelong anticoagulation. No evidence in support of this recommendation is cited.

Brown and Bevan recommend repeating measurements of protein C, protein S, and antithrombin III for at least 3 months after the acute event but depressed concentrations returning to normal between 12 and 24 months after childhood stroke have previously been reported.²⁻⁷ It would therefore seem prudent to follow concentrations of protein C and protein S for at least this time period before concluding that they can be attributed to an inherited thrombophilia, particularly if the presence of such a disorder is to be managed by "lifelong anticoagulation".

C R KENNEDY

Department of Paediatric Neurology, Southampton General Hospital, Southampton, UK

- 1 Ganesan V, McShane MA, Liesner R, *et al*. Inherited prothrombotic states and ischaemic stroke in childhood. *J Neurol Neurosurg Psychiatry* 1998;65:508-11.
- 2 Kennedy CR, Warner G, Kai M, *et al*. Protein C deficiency and stroke in early life. *Dev Med Child Neurol* 1995;37:723-30.
- 3 Chancellor AM, Glasgow GL, Okelford PA, *et al*. Etiology, prognosis and hemostatic function after cerebral infarction in young adults. *Stroke* 1989;20:477-82.
- 4 Camerlingo M, Finazzi G, Casto L, *et al*. Inherited protein C deficiency and non-haemorrhagic arterial strokes in young adults. *Neurology* 1991;41:1371-3.
- 5 Brown MM, Bevan D. Is inherited thrombophilia a risk factor for arterial stroke? *J Neurol Neurosurg Psychiatry* 1998;65:617.
- 6 Israels SJ, Seshia SS. Childhood stroke associated with protein C or S deficiency. *J Pediatr* 1987;111:562-4.
- 7 Dusser A, Boyer-Neumann C, Wolf M. Temporary protein C deficiency associated with cerebral arterial thrombosis in childhood. *J Pediatr* 1988;113:849-51.

Lyme borreliosis and intracranial aneurysm

We read the article by Oksi *et al*¹ describing three patients with *Borrelia burgdorferi* infection and intracranial aneurysms with great interest. We encountered a patient with neuroborreliosis and an aneurysm of the basilar artery, whom we describe.

A previously healthy 33 year old man presented with headache and progressive right hemiparesis. On neurological examination

there was right facial weakness, moderate weakness of the right arm and leg (3/5), and brisk deep tendon reflexes. A right Babinski's sign was present. Cerebral CT and MRI showed left anterior infarction, without enhancement with contrast. Examination of CSF disclosed 246 leucocytes/mm³; the protein content was 3.49 g/l. The IgG index was raised to 1.35. The CSF was xanthochromic, because of bilirubin. IgG antibodies against *Borrelia burgdorferi* in CSF were detected. A cerebral angiogram showed narrowing of the left anterior cerebral artery and an aneurysm of the basilar artery. Serum IgG antibodies against *Borrelia burgdorferi* were detected. Investigations for other disorders were normal. We concluded that our patient had neuroborreliosis and he was treated with ceftriaxone intravenously for 14 days. There was an almost complete recovery.

The diagnosis of neuroborreliosis in this patient is supported by the clinical presentation with right hemiparesis, positive serology for *Borrelia burgdorferi*, the presence of IgG antibodies against *Borrelia burgdorferi* in the CSF, and the response to antibiotic treatment. Based on the article by Oksi *et al*,¹ it is very appealing to explain what happened in our patient by using their concept. Our patient had an aneurysm of the basilar artery. If vasculitis is one of the primary pathological mechanisms in neuroborreliosis, it can also lead to formation of aneurysms or vascular infarction.

However, we postulate that the presence of the aneurysm in our patient was a coincidence. There are two other explanations for the xanthochromia through bilirubin in his CSF. The first is the raised protein content of the CSF (in a patient with a meningitis due to neuroborreliosis). Or, our patient had a vasculitis (supported by the pleiocytosis of the CSF and by the narrowing of the left anterior cerebral artery on angiogram) which can lead to subarachnoid haemorrhage without the presence of an aneurysm, as was shown by Chehrenama *et al*.²

A causal relation between neuroborreliosis and the aneurysm is only based on circumstantial evidence. We do not agree that the reported cases of Oksi *et al* support this relation. Firstly, we think that only one of the three patients had neuroborreliosis. In the other two patients there was no pleiocytosis or raised protein content in the CSF, a finding that is considered to be a necessity for the diagnosis of neuroborreliosis.³⁻⁵ Also, antibodies against *Borrelia burgdorferi* were not detected. Besides this, no evidence exists that in the one patient with neuroborreliosis and subarachnoid haemorrhage there is a causal relation with the aneurysm. He could indeed be one of those patients who happen to have an aneurysm.

For now, the answer to the question: "Intracranial aneurysms in three patients with disseminated Lyme borreliosis: cause or chance association?" should be chance association.

JOSÉ D POLET

HENRI C WEINSTEIN

Department of Neurology, Saint Lucas Andreas Hospital, Amsterdam, The Netherlands

Correspondence to: Dr J D Polet, Saint Lucas Andreas Hospital, Department of Neurology, Jan Tooropstraat 164, 1061 AE Amsterdam, The Netherlands.

- 1 Oksi J, Kalimo H, Marttila RJ, *et al*. Intracranial aneurysms in three patients with disseminated Lyme borreliosis: cause or chance association? *J Neurol Neurosurg Psychiatry* 1998;64:636-42.

- 2 Chehrenama M, Zagardo MT, Koski CL. Subarachnoid hemorrhage in a patient with Lyme disease. *Neurology* 1997;48:520-3.
- 3 Tumani H, Nolker G, Reiber H. Relevance of cerebrospinal fluid variables for early diagnosis of neuroborreliosis. *Neurology* 1995;45:1663-70.
- 4 Garcia-Monco JC, Benach JL. Lyme neuroborreliosis. *Ann Neurol* 1995;37:691-702.
- 5 Hansen K. Lyme neuroborreliosis. *Acta Neurol Scand* 1994;89(suppl 151):30-3.

Oksi *et al* reply:

As a reply to the comments by Polet and Weinstein on our article "Intracranial aneurysms in three patients with disseminated Lyme borreliosis: cause or chance association?" we present the following comments.

Polet and Weinstein consider that only one of our three patients had neuroborreliosis. In our article¹ we do not claim that all the patients had neuroborreliosis. However, all three patients had disseminated Lyme borreliosis based on the detection of *Borrelia burgdorferi* DNA in plasma samples of two patients, and an intrathecal production of antibodies against *Borrelia burgdorferi* in the third patient. It is also relevant to raise the question: what is neuroborreliosis? Does it require invasion of the spirochetes to none, one, or several of the following: cerebral tissue, meninges, CSF, or vessels in the central (or peripheral) nervous system. The authors state that an increased cell count or increased protein content is a necessity for neuroborreliosis, referring to the article by Garcia-Monco and Benach. However, this is not always the case as shown, for example in the studies by Luft and Coyle in which they describe patients with neuroborreliosis having DNA or antigens of *Borrelia burgdorferi* in CSF despite normal routine CSF analysis and absence of antibodies against *Borrelia burgdorferi* in CSF.^{2,3}

Polet and Weinstein present a case of a patient with an intracranial aneurysm and suspected neuroborreliosis. They write that antibodies against *Borrelia burgdorferi* were detected in the CSF. However, the total IgG was increased, and they do not state whether the antibodies were intrathecally produced or not. If we understood correctly, the authors think that they, for some reason, could associate the focal narrowing of the left anterior cerebral artery with *Borrelia burgdorferi* but could not do the same with the aneurysm of the basilar artery. They do not have any evidence that excludes the possibility that the aneurysm could also have been caused by *Borrelia burgdorferi*. As we refer to in our article, high numbers of inflammatory cells have been found in aneurysms.⁴ We consider that it is possible that the aetiology of inflammatory changes in both instances may be the same—although probably seen at a different time point. We and others have found that disseminated Lyme borreliosis may be associated with cerebral vasculitis.⁵

Polet and Weinstein give a straightforward answer to the question presented in the title of our article. However, we think that it is not yet possible to give an answer to this question. The previously known association of another spirochetal infection, syphilis, to aneurysm formation, indicates that there might be a causal relation between *Borrelia burgdorferi* infection and aneurysm formation. This possible causal relation is a hypothesis that could be tested in the future in a larger number of patients with coexisting aneurysm and Lyme borreliosis. Definite answers would require analysis of a sufficient number of aneurysms

samples using adequate techniques—for example, the polymerase chain reaction.

JARMO OKSI
Department of Internal Medicine, Turku University
Central Hospital
and Department of Medical Microbiology, Turku
University, Finland

HANNU KALIMO
REIJO J MARTTILA
MERJA MARJAMÄKI
PIRKKO SONNINEN
JUKKA NIKOSKELAINEN
MATTI K VILJANEN

Turku University, Turku University Central Hospital,
and National Public Health Institute, Department in
Turku, Finland

- Oksi J, Kalimo H, Marttila RJ, et al. Intracranial aneurysms in three patients with disseminated Lyme borreliosis: cause or chance association? *J Neurol Neurosurg Psychiatry* 1998;64:636–42.
- Luft BJ, Steinman CR, Neimark HC, et al. Invasion of the central nervous system by *Borrelia burgdorferi* in acute disseminated infection. *JAMA* 1992;267:1364–7. Comment in: *JAMA* 1992;268:872.
- Coyle PK, Schutzer SE, Deng Z, et al. Detection of *Borrelia burgdorferi*-specific antigen in antibody-negative cerebrospinal fluid in neurologic Lyme disease. *Neurology* 1995;45:2010–5.
- Kosierkiewicz TA, Factor SM, Dickson DW. Immunocytochemical studies of atherosclerotic lesions of cerebral berry aneurysms. *J Neuropathol Exp Neurol* 1994;53:399–406.
- Oksi J, Kalimo H, Marttila RJ, et al. Inflammatory brain changes in Lyme borreliosis. A report on three patients and review of literature. *Brain* 1996;119:2143–54.

A video is an excellent addition to any book on movement disorders. Unfortunately, the video refused to run on our modern video recorder at home (which never refuses offerings from the Disney corporation) and ran poorly on the state of the art equipment at Addenbrooke's Hospital. Some of the clips were of poor quality—perfectly acceptable for very rare diseases but not for common conditions. The video covered the basics well and had some particularly florid examples of ticeurs. More cross referencing between the book and video would have helped.

Despite its limitations I would recommend this book-video combination for the groups at whom it is aimed—namely, primary care physicians and doctors in training. However, I thought that it might have been better written by a far smaller team, leaving the multieditor/multi-author approach for more advanced textbooks, which aim to become the definitive works on a subject.

JERRY BROWN

Biology: Brain and Behaviour—The Brain: Degeneration, Damage and Disorder. Edited by JUDITH METCALFE. (Pp 270, £26.00). Published by Springer-Verlag, Heidelberg, 1998. ISBN 3-540-63796-6.

Biology: Brain and Behaviour—Neurobiology. Edited by DAVID ROBINSON. (Pp 372, £26.00). Published by Springer-Verlag, Heidelberg 1998. ISBN 3-540-63546-7.

Biology: Brain and Behaviour—The Senses and Communication. Edited by TIM HALLIDAY. (Pp 237, £26.00). Published by Springer-Verlag, Heidelberg, 1998. ISBN 3-540-63775-3.

These three books and CD-ROM form part of a six book series for the Open University course on Biology: Brain and Behaviour. Book 2, *Neurobiology*, covers the biophysical properties of the neuron, before dealing with neural networks and the relation of the CNS to the immune system and behaviour. Book 3 runs through the senses, with the discussion concentrating on the audition, vision, and somatosensory systems. The final book in the series deals with disease processes of the brain and mind. The books not reviewed comprise the first book in the series entitled *Behaviour and Evolution* and books 4 and 5 on *Development and Flexibility and Control of Behaviour*. The six books are therefore written for a specific audience, which is clearly reflected in the format of the text and figures. However, this having been said, these books are easily accessible to other students interested in neuroscience, although the way the book is packaged and presented would put most people off purchasing them, which is a shame.

Each chapter is clearly presented with high quality figures, which are often superior to those found in most medical neurobiology books. Furthermore, they often summarise key experimental results in a clear and concise fashion, and coupled to the well written prose, makes the book easy to understand and follow, if somewhat verbose. Questions are thrown in throughout the text and each chapter concludes with a summary, an objectives list, and a series of questions with a few

key references cited. In addition, these books were impressive in their breadth of discussion within individual topics. For example, the pain section not only covers the conventional anatomical and pharmacological aspects of nociception but also discusses a range of antinociceptive treatments and strategies. As a result the reader is left with a much more balanced view than that which is traditionally presented in preclinical medical training and which is often at variance with that which is seen in clinical practice. It is this aspect of the books that is perhaps of most value and which could be applied to the new style of medical training currently being developed in this country. However constraints on time make it hard to commend all the details raised in these books, although the accompanying CD-ROM is a helpful innovation in this respect. Overall these books and CD-ROM make an attractive package which is lost to most students and teachers as a result of it being used for a specific Open University course. However, there is much of value in this series for those interested in the education of medical students.

ROGER BARKER

Electrocorticography: Current Trends and Future Perspectives. Edited by LF QUESNEY, CD BINNIE, and G-E CHATRIAN. (Pp 172, US \$161.00). Published by Elsevier Science, Amsterdam 1998. ISBN 0 444 82509 6.

This is a book of 172 pages dedicated to the memory of Frank Morrell. It is a multi-author text, originating largely from North America (with a notable United Kingdom contribution from the Maudsley Hospital). After a historical review including stimulation and recording techniques, novel approaches to using electrocorticography to predict surgical outcome after temporal lobe resection are presented convincingly and then followed by another chapter showing how parallel approaches can be applied in tailored resections. Electrocorticography findings in extratemporal epilepsy are then dealt with, confirming that restricted frontal lobe abnormalities predict a favourable outcome, particularly when combined with a well defined structural lesion. The technique of chronic electrocorticography is also reviewed, including a demonstration of how important it can be to define the limits of interictal epileptiform activity and the ictal onset zone if a complete resection of the structural lesion is not possible.

The disparate results in clinical studies using pharmacological activation are then considered, but sensible conclusions are drawn about the relatively minor role of this approach in determining the limits of a potential cortical excision, showing that this book keeps its feet on the ground where necessary.

A comprehensive multicentre contribution follows, describing the findings in cortical dysplasia, and the way these probably limit the surgical outcome when compared with patients with other structural lesions. There are then three chapters on studies in the mesial temporal region, involving patient selection, prognosis, volumetric MRI, and a combination of acute and chronic electrocorticography techniques. Some of this is then applied to a chapter on hemispherectomy.

The book finishes with a chapter on the applications of image guided surgery to

BOOK REVIEWS

Differential Diagnosis and Treatment of Movement Disorders. (Book and Video Set). Edited by EDUARDO TOLOSA, WILLIAM C KOLLER, and OSCAR S GERSHANIK. (£90.00). Published by Heinemann, Oxford, 1998. ISBN 0-7506-9971-X.

First impressions count, so it is important for a publisher to choose the right time to send a book to be reviewed. Unfortunately Butterworth Heinemann's timing for this book was awry. This volume arrived on my desk at the same time as I was struggling to improve a patient's primary orthostatic tremor in time for her daughter's wedding in Australia. I was therefore disconcerted when I could find no reference to this disease in the index under primary, orthostatic, or tremor. I turned to the chapter on tremor and eventually found a single inadequate sentence describing it as a clinical variant of essential tremor and a reference to clonazepam as the first line treatment. Happily, the book passed my second test—treatment options for a patient with tardive dyskinesia.

With longer acquaintance the book is more impressive. There are some good reviews and some authors have taken much trouble to produce treatment algorithms. I thought that many of the tables were excellent. A physician using the book for guidance for a patient with Parkinson's disease, multiple system atrophy, or dystonia would find an abundance of useful information. However there are unfortunate lacunae—for example, there is no mention of the recent controversies over the use of selegiline.

intraoperative electrophysiology, which is probably one of the most spicy contributions, confirming that a multimodal approach to the application of these investigations will probably be the most fruitful approach in the medium term. Those units contemplating similar work will find this book very useful in terms of selecting some of the techniques that they intend to include or exclude, with natural effects on their resources and clientele. Specialised units which already perform similar work will also find this a useful review. Inevitably this book will be of interest to a relatively selective readership, to whom it is thoroughly recommended.

SIMON BONIFACE

Intracranial and Inner Ear Physiology and Pathophysiology. Edited by ANDREW REID, ROBERT J MARCHBANKS, and ARNE ERNST. (Pp 316, £50.00). Published by Whurr Publishers Ltd, London 1998. ISBN 1 86156 066 4.

The complex relations between intracranial and inner ear fluids are fascinating for both the scientist and the clinician. This volume represents the Proceedings of the Second International Conference on Intracranial and Inner Ear Fluids, which was held in Bath, UK in June 1997, and accurately reflects the sense of enthusiasm and collaboration at that meeting. The contributors include neurosurgeons, audiologists, otologists, neurologists, epidemiologists and basic scientists, and the scope of the material is very impressive.

The book comprises four sections. The first, *intracranial physiology*, contains four chapters including a very clear review of the anatomy and physiology of intracranial fluids by Segal, and then three examples of experimental work on cats, guinea pigs, and humans. The second section, *intracranial pathophysiology*, opens with a review of "Pathophysiology of the cerebrospinal and cerebrovascular circulations" by Pickard *et al*, and then eight chapters considering related topics. The tympanic membrane

displacement (TMD) test procedure is discussed, representing a non-invasive method of assessing intracranial fluid pressure, and particularly useful in the assessment of shunt malfunction. The third section, *inner ear physiology*, contains 10 chapters, and considers the inner ear fluids, perilymph, and endolymph in very considerable detail. The final section, *inner ear pathophysiology*, is perhaps the least consistent in the volume and at times strays from the fluid remit of the book. It does, however, contain a very useful chapter considering the Tullio phenomenon (by O'Mahoney and Luxon) that deserves careful study.

For anyone interested in the areas described above this book will be interesting and useful. Collaboration and indeed communication between those interested in the intracranial fluids and inner ear fluid is in its infancy, and whereas this book does contain exciting material there is little that is of clinical relevance yet, although some of the techniques and concepts described hold great promise. Many departmental libraries would benefit from the inclusion of this volume, although only those directly involved in this area would be able to justify a private purchase.

DAVID BAGULEY

Memory in Neurodegenerative Disease.

Edited by ALEXANDER I TROSTER. (Pp 413, £60.00 (US \$95.00)). Published by Cambridge University Press, Cambridge 1998. ISBN 0-521-57192-8.

No one can doubt the increasing importance, to affected families and the healthcare system, of Alzheimer's disease, Parkinson's disease, and the other degenerative conditions of the nervous system. Furthermore, study of the degenerating brain can provide fundamental insights into brain function. Although there are authoritative books on memory, on disorders of memory, and on the neurological diseases covered in this book, the strength of the book is in the accounts of different views of memory in neurodegenera-

tive disease. These differing perspectives mean that this book will be of interest to neurologists, neuropsychologists, psychiatrists, and researchers in the neurosciences.

The book is divided into three broad sections with summary chapters at the end of each. The first section deals with the biological aspects of neurodegenerative disease, with reviews on neuropathology, animal models, neurochemistry, and neuroimaging.

The two chapters on neuroimaging are particularly valuable, being clear and well referenced. Although the genetic advances in this area are mentioned in several chapters, it is not a major topic in this work.

The second section reviews the different cognitive aspects and explores the role of neurodegenerative conditions in the understanding of organisation of memory. Executive functions in both subcortical and cortical dementia syndromes, episodic and semantic memory, and non-declarative memory are systematically covered. The discussion of disintegration of distinct memory systems in different degenerative conditions will be of interest to psychologists and doctors alike, although this section will be of special interest to neuropsychologists.

The last section of this book will be particularly useful for clinicians, as there are admirable summaries of the assessment of memory, including very interesting accounts of cross cultural issues in neuropsychological assessment and the reliability of psychometric instruments. The important clinical issues of early detection and of differentiating dementias and memory disorders are well presented. This section ends with an exploration of drug and surgical treatments for neurodegenerative disease.

There is particular consideration of the possible cognitive sequelae of neurosurgery for akinetic-rigid syndromes and tremor. I would recommend this book to anyone who wants a clear and authoritative account of the role of neuropsychology, experimental psychology, and theories of memory structure and organisation in relation to the neurobiology of the dementias and other neurodegenerative conditions.

CLARE GALTON