Journal of Neuro-Ophthalmology 17(2): 108–121, 1997.

Neuro-ophthalmic Manifestations of Lyme Disease

Laura J. Balcer, M.D., Jacqueline M. S. Winterkorn, Ph.D., M.D., and Steven L. Galetta, M.D.

Lyme disease is a multisystem disorder caused by infection with the *Borrelia burgdorferi* spirochete. The diagnosis of Lyme disease usually is based on several clinical criteria, with supportive data from laboratory testing. The presence of the bullseye skin lesion, erythema migrans, is the single pathognomonic criterion. In the 20 years since the initial description of Lyme disease in the United States, *B. burgdorferi* has been implicated as an etiologic agent in numerous ophthalmic and neuro-ophthalmic syndromes, involving most structures from the cornea to the cranial nerves. Neuro-ophthalmic and ocular manifestations of Lyme disease include meningitis with papilledema, cranial neuropathies, follicular conjunctivitis, nummular keratitis, and intraocular inflammation. Although an association with Lyme disease has been purported for numerous other syndromes, a definite causal relationship has not been proved in many cases. During a period of rapidly increasing awareness of Lyme disease, a high index of suspicion and poorly defined criteria for its presence have resulted in overdiagnosis of Lyme disease. In the authors' experience, the incorrect diagnosis of Lyme disease initially has been made in patients with allergic conjunctivitis, keratoconus, morning glory syndrome, craniopharyngioma, meningioma, CNS lymphoma, paraneoplastic syndrome, multiple sclerosis, sarcoid, syphilis, and functional illness. Nevertheless, this treatable infection must be an important consideration in the differential diagnosis of certain ocular or neurologic diseases.

Key Words: Lyme disease—Erythema migrans—Meningitis—Cranial neuropathy—Optic neuropathy—Ocular inflammation.

Lyme disease was first described in the United States in 1977, when Steere et al. (1) reported an epidemic form of arthritis occurring in 51 residents of three contiguous communities in Connecticut. The investigation was prompted in part by a report to the state health department by mothers from Old Lyme, Connecticut, who voiced concern that 12 children in that small community of 5,000 residents had been diagnosed with juvenile rheumatoid arthritis. Epidemiologic evaluations as well as the observation that the pathognomonic skin lesion, erythema migrans (EM), had preceded the illness suggested transmission by an arthropod vector (1).

The infectious agent in Lyme disease was identified as the spirochete *Borrelia burgdorferi* (2–4), and its transmission was traced to two important species of *Ixodes* tick in the United States, *Ixodes scapularis* (formerly called *Ixodes dammini*) in the east and *Ixodes pacificus* in the west (5,6). The principal hosts for *Ixodes* ticks include white-footed mice (for larval and nymph stages) and white-tailed deer (for adult ticks) (4–8). Although studies have shown that deer have a definite role in the maintenance of *I. scapularis* populations (6,9,10), deer appear to be incapable of infecting ticks with *B. burgdorferi* (6,11).

Infection of the tick population with *B. burgdorferi* seems increasingly prevalent in endemic areas. In the northeastern United States, as many as 35 to 65% of field-collected *I. scapularis* nymphs and adults may be infected with *B. burgdorferi* (4,6). For example, in a study of *Ixodes* ticks in the Philadelphia area (12), 88% of 42 ticks sampled in Montgomery County carried the spirochete. In contrast, because *I. pacificus* ticks in the west feed primarily on lizards, which are incompetent as reservoirs for *B. burgdorferi*, the prevalence of infection in these tick populations is only 1 to 3% (4–6). Although the infectivity rate of *I. scapularis* nymphs is only half that of adult ticks, human infection with Lyme disease is attributed to the nymph stage in nearly 90% of disease cases transmitted by this *Ixodes* species (13), reflecting in part the smaller size and greater abundance of nymphs compared with adults (6). Furthermore, the peak feeding activity of the nymph stage is during the months from May to July, corresponding to the season of increased human outdoor activity in the northeast (6). The infection is most commonly acquired between May and July and less often is transmitted by adult ticks during autumn.

Lyme disease has a worldwide distribution. According to a recent report from the Centers for Disease Control (CDC) (14), 11,603 cases of Lyme disease were reported in the United States in 1995, with an overall incidence of 4.4 per 100,000 population. Cases were reported in 43 states and the District of Columbia (14); however, 92% of cases occurred in the highly endemic areas of Con-

Manuscript received December 1995; accepted August 14, 1996.

From the Division of Neuro-Ophthalmology (L. J. B., S. L. G.), Departments of Neurology and Ophthalmology, Hospital of the University of Pennsylvania and Scheie Eye Institute, University of Pennsylvania School of Medicine, Philadelphia, Pennsylvania; and Departments of Neurology and Ophthalmology (J. M. S. W.), The New York Hospital-Cornell Medical Center, New York, New York, U.S.A.

Address correspondence and reprint requests to Dr. Laura J. Balcer, Department of Neurology, University of Pennsylvania Medical Center, 3400 Spruce Street, Philadelphia, PA 19104, U.S.A.

necticut, Rhode Island, New York, New Jersey, Pennsylvania, Maryland, Wisconsin, and Minnesota (14). The number of reported cases of Lyme disease in the United States has steadily increased between 1982 and 1995 (14). Nevertheless, Lyme disease remains uncommon in most regions of the United States (6,14,15).

Men, women, and children of all ages have been infected by the *B. burgdorferi* spirochete (4,14). In the United States in 1995, nearly 50% of reported cases included children aged less than 14 years and adults aged 35 to 49 years (14). Contributing to the difficulty of diagnosis, most patients with Lyme disease may not recall the bite of the tick, and particularly infection by the tiny nymph stage may have gone unnoticed (16,17). Lyme disease is now recognized as a multisystem infection that is characterized by prominent dermatologic, neurologic, cardiac, and rheumatologic manifestations (16,17). Although minor ocular symptoms have been recognized since the earliest reports of Lyme disease, serious ocular manifestations of Lyme disease are uncommon (17). In the early enthusiasm for making the diagnosis of Lyme disease, a high index of suspicion and poorly defined criteria for its presence resulted in overdiagnosis of Lyme disease, as stressed by Winterkorn for neuro-ophthalmic and ocular diagnoses (16–19) and by Steere and colleagues for systemic manifestations (20). In the authors' experience, the incorrect diagnosis of Lyme disease initially is made in patients with allergic conjunctivitis, keratoconus, morning glory syndrome, craniopharyngioma, meningioma, CNS lymphoma, paraneoplastic syndrome, multiple sclerosis, sarcoid syphilis and other bacterial infections, and functional illness. Physicians are now beginning to place this disorder in perspective, giving Lyme disease less emphasis as a possible cause for many neurologic and ophthalmic signs and symptoms. Although the potential for overdiagnosis exists, this treatable infection is an appropriate consideration in the differential diagnosis of many ophthalmic and neuro-ophthalmic syndromes, especially in regions where the infection is endemic.

DIAGNOSIS OF LYME DISEASE

The most important historical feature indicating the diagnosis of Lyme disease is the rash, EM (Fig. 1), an expanding erythematous lesion that occurs at the site of a tick bite an average of 8 to 9 days (range, 2–28 days) after infection (21–23). It begins as a small macule and expands over several days to form a large erythematous plaque, typically of annular configuration, with a characteristic central area of clearing or hypopigmentation. Although EM has been considered the only pathognomonic criterion for the diagnosis of Lyme disease, only 60 to 80% of patients notice the skin lesion (4,21), which is usually asymptomatic and only occasionally pruritic, tender, or painful; so it may be ignored by the patient if it is on the back or hidden by clothing. The EM rash itself may persist or recur for weeks or months, but typically it resolves in days with appropriate antibiotic therapy (24). Erythema migrans is often accompanied by flu-like symptoms, including fatigue (54%), myalgias (44%), arthralgias (44%), headache (42%), fever and chills (39%), and regional lymphadenopathy (23%) (4,22,23). Although such symptoms also can occur in the absence of EM, their incidence in Lyme disease is unknown (23).

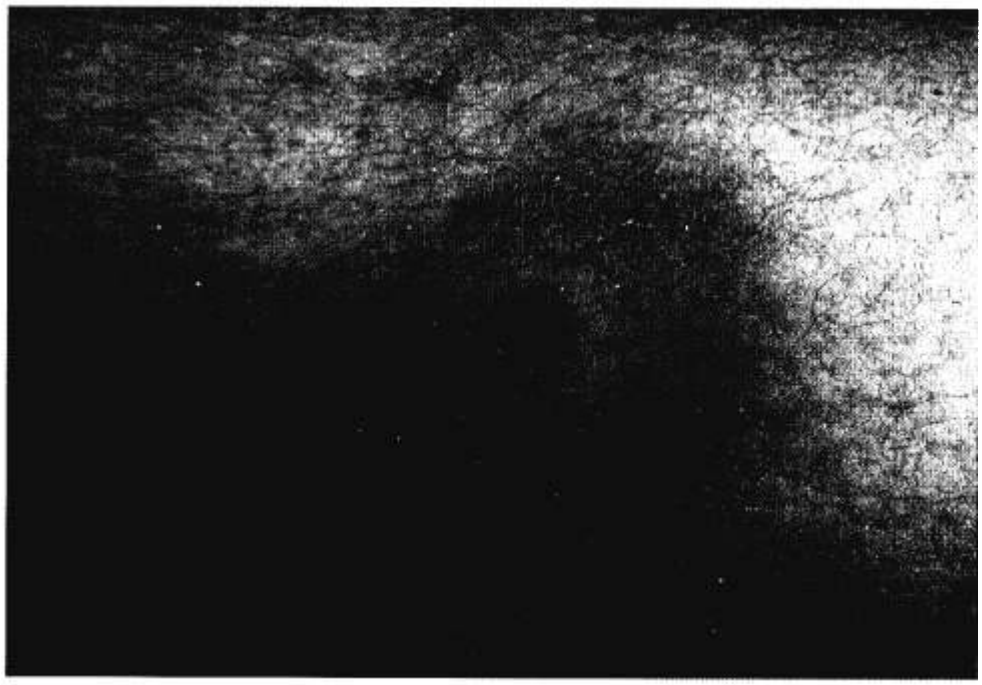

FIG. 1. Color photograph of erythema migrans (EM) rash demonstrating annular erythema with central area of hyperpigmentation. (Photograph courtesy of William James, M.D.)

The diagnosis of Lyme disease is made difficult by the infrequency with which the spirochete can be directly demonstrated. The Lyme spirochete has been cultured successfully from spinal fluid, blood, and synovial fluid (4,25,26). Culture of *B. burgdorferi*, although 100% specific, has a sensitivity of only 10% under ideal conditions (26,27). *B. burgdorferi* has been identified by silver staining in the retina, vitreous, brain, and skin (28,29), but even carefully done, silver stains are notoriously subject to misinterpretation (4,16,17,26).

Laboratory diagnosis of Lyme disease is usually attempted through blood testing. An enzyme-linked immunosorbent assay (ELISA) for IgM and IgG antibodies against *B. burgdorferi* has been the most common serologic test (4,21,26,30–32). The more direct and sensitive ELISA capture assay is now the preferred technique (33). Despite the superior sensitivity and specificity (21,32) of ELISA compared with indirect fluorescent antibody staining, interpretation of ELISA results is nonetheless confounded by the absence of consistency among different laboratories and the presence of false-positive reactions in patients with syphilis and other infections (16, 21,22,31,32). Because of cross reactivity with syphilis, some authors have recommended that the Venereal Disease Research Laboratory test (VDRL) and microhemagglutination-*Treponema* (MHATP) or fluorescent treponemal antibody absorption test (FTA-ABS) be measured concomitantly with Lyme ELISA in patients with suspected Lyme disease (16,17,34); and in endemic areas, serologic tests for Lyme disease should be obtained in patients with suspected syphilis (17,35,36).

To confirm or to clarify the results of an ELISA, Western blot analysis is used. This technique, which identifies antibody responses to key immunodominant proteins on *B. burgdorferi*, is particularly helpful in differentiating false-positive from true-positive ELISA serologies, especially when the ELISA results are in the low-positive or borderline range (14,26,30–32); however, the use of Western blot analysis is neither informative nor recommended when a reliable ELISA has proved negative (21,26). Criteria for defining a positive IgG or IgM Western blot for *B. burgdorferi* antigens have been recommended recently by a working group of the CDC, as outlined by Halperin and colleagues (26,30).

The latest laboratory techniques for the diagnosis of Lyme disease emphasize the detection of the *B. burgdorferi* spirochete itself or its components rather than the detection of antibodies. Polymerase chain reaction (PCR) is one such method that is being evaluated to determine whether *B. burgdorferi* DNA from a small number of spirochetes can be amplified to improve detection in blood, spinal fluid, skin, and other tissues (31). Because PCR can amplify DNA from dead organisms, a positive result does not necessarily indicate active *B. burgdorferi* infection (26,31). Despite the potential utility of this technique, PCR is not routinely available at most centers, and additional work is needed to reduce the potential for false-negative and false-positive reactions (26,31).

The early diagnosis and immediate treatment of Lyme disease may prevent its dissemination and subsequent development of significant clinical sequelae. Unfortunately, antibodies to *B. burgdorferi* usually are not detectable until 4 to 6 weeks after the initial infection (22), and initial serum samples from nearly 50% of patients who have EM or early constitutional symptoms may be negative (21–23,31,32). Furthermore, in locales where Lyme disease is highly endemic, the rate of seropositivity in currently uninfected persons may be as high as 10% (26). When neurologic signs are present, assay of intrathecal antibody synthesis may be helpful in determining whether a positive serum titer is related to present neurologic signs or merely reflect previous infection (17, 26,31,37,38). Serologic testing alone (ELISA or Western blot analysis) is useful in confirming the presence of Lyme antibodies, but results often do not correlate with the degree of disease activity or with the success of prior treatment. Therefore, the diagnosis of Lyme disease is based on clinical criteria, with laboratory tests used to provide supportive data (21,26,30,32).

Recognizing that a significant proportion of patients may be unaware of the tick bite, EM may be absent, and serologies may be negative or falsely positive, formal diagnostic criteria have been established to aid clinicians and epidemiologists in the consistent and rational diagnosis and study of Lyme disease (16,21,26,32,39,40). In 1982, the CDC established a surveillance case definition for Lyme disease, which emphasized the importance of exposure in an endemic area (32). Although patients with EM and negative serologies in nonendemic areas may be excluded by these criteria, patients with positive Lyme titers but unrelated symptoms and signs may be inappropriately assigned this diagnosis. A uniform definition is essential for epidemiologic studies and clinical trials, but its strict application does not eliminate diagnostic errors in the clinical setting (16,32). Clinical judgment, rather than strict adherence to case definitions or rigid reliance on serologic testing, must direct decisions regarding the diagnosis of Lyme disease.

Guidelines have been proposed for the diagnosis of neuroborreliosis in patients with CNS dysfunction (26). According to these guidelines, the following criteria must be met to make the diagnosis of Lyme disease as the cause of the neurologic findings: (a) possible exposure in an endemic area; (b) EM rash, positive serologic test, or positive culture/PCR; and (c) presence of neurologic disease that has been shown to be causally related. These authors have also emphasized that intrathecal antibody almost always is present in cases in which Lyme disease is the cause of a chronic neurologic syndrome.

Lesser (40) recently suggested criteria that may be helpful in establishing that ocular findings can be attributed to Lyme disease: (a) lack of evidence of other diseases to explain ocular findings, (b) other clinical findings consistent with Lyme disease, (c) occurrence in patients living in an endemic area or with history of travel to an endemic area, (d) positive Lyme serology, and (e) response to treatment (in most cases). These criteria are not designed as an all-inclusive or strict case definition

but may be useful to keep in mind when evaluating patients or when critically reviewing the neuro-ophthalmic literature. Although many neurologic and ophthalmic signs and symptoms have been associated with Lyme disease, conservative diagnostic criteria such as these rarely have been fulfilled, and in most cases a definite causal relationship has not been proved (16,17,26).

REVIEW OF OPHTHALMIC AND NEURO-OPHTHALMIC MANIFESTATIONS

The clinical manifestations of Lyme disease have been divided into three chronologic stages, analogous to syphilis (4,16); however, not all patients with Lyme disease pass through each stage, and the symptoms and signs attributed to each stage are extremely varied. It may be more useful, therefore, to refer to the clinical signs and symptoms of Lyme disease simply in terms of early and late manifestations, as suggested in recent reviews by Winterkorn (17), Lesser (40), and Bergloff et al. (41). Early Lyme disease includes stage I with the appearance of EM, the pathognomonic skin rash that indicates infection and often is accompanied by flu-like symptoms (see Diagnosis). Stage II of early Lyme disease is characterized by signs of dissemination of the infection to various systems. Prominent manifestations include neurologic (especially meningitis, cranial neuropathies, radiculoneuropathy), cardiac, rheumatologic, and occasionally ocular signs. Late Lyme disease or stage III appears months to years after initial infection and most frequently is characterized by chronic arthritis, acrodermatitis chronica atrophicans, and encephalomyelitis. This classification will be used in the following descriptions of the major ophthalmic and neuro-ophthalmic features of Lyme disease.

Follicular Conjunctivitis

Follicular conjunctivitis has been reported in 10 to 11% of patients with EM and flu-like symptoms of early Lyme disease, and it may occur even more frequently (1,25,42–47). Patients complain of photophobia, and examination has demonstrated periorbital edema and episcleritis. Subconjunctival hemorrhages also have been reported both in isolation and in association with conjunctivitis (40,42). Conjunctivitis and episcleritis in early Lyme disease are most often mild, self-limited, and do not require topical antibiotic treatment.

Keratitis

In contrast to conjunctivitis, which occurs as a feature of early Lyme disease, keratitis has been reported to occur months or years after the onset of infection and is a manifestation of late Lyme disease (16,17,19,20,40,41, 48,49–55). Although keratitis is perhaps the best documented ocular finding, and indeed the only ocular sequela reported in untreated Lyme disease, it remains a relatively rare manifestation of Lyme disease.

The keratitis associated with Lyme disease is characterized by bilateral scattered hazy infiltrates in the deep and superficial stroma without involvement of Descemet's membrane (19,20,47–53,56–58). Unlike the keratitis typically associated with syphilis, the Lyme keratitis is mild and corneal neovascularization is infrequent (41, 48,52,59). Although the entire cornea may be involved, the visual axis is usually spared (52). Cases of keratitis attributed to Lyme disease do not seem to involve active infection with the spirochete and are treated successfully with steroids alone, suggesting an immune pathogenesis for this late manifestation (19,48–51,53–55,60,61).

Other forms of keratitis have been described for which a causal relationship with Lyme disease is less certain (17). Bilateral interstitial keratitis in association with hearing loss, vertigo, and tinnitus (Cogan's syndrome) has been reported in one seropositive patient (54). Peripheral ulcerative keratitis, commonly seen in autoimmune diatheses, was described in a woman who later developed vasculitis requiring treatment with azathioprine (41,60). In addition, unilateral or bilateral VIIth nerve palsy (discussed below) can lead to an exposure keratitis (40).

Intraocular Inflammation

Patients with a variety of ocular inflammatory syndromes have been shown to have positive Lyme serology, and ocular inflammation involving almost every part of the eye has been attributed to Lyme disease (16,17,35,40,41,62–64). Manifestations of uveitis reported in patients with positive Lyme serologies include iridocyclitis, iritis, and granulomatous iritis (28,34–36,41,43,56,59,62,65–71); pars planitis or intermediate uveitis (35,36,46,56); vitritis (35,36,41,46,65,72,73); and panophthalmitis (28,59,69,71).

Studies of animals infected with *B. burgdorferi* have shown that early in the course of disease, when the spirochete disseminates throughout the body, it invades the eye, where it may remain dormant, and possibly immunologically sequestered (74,75). The possibility of a special immune status for intraocular borrelia is worrisome but perhaps supported by the identification of spirochetes in the vitreous of two patients with vitritis, one of whom was seronegative (28,59,76). The severe unilateral panendophthalmitis described by Kauffmann et al. (28,59) developed in a woman with a history of insect bite and EM, for which the patient had received antibiotic treatment; *B. burgdorferi* were not found in a vitrectomy specimen in this case but were identified in vitreous debris after enucleation. Recent isolation of *B. burgdorferi* from an iridectomy specimen of a patient with anterior uveitis is strong proof that Lyme disease can cause iritis (77).

The cause of any particular case of uveitis frequently remains unknown despite thorough evaluation for infectious, inflammatory, and neoplastic processes. Although Lyme disease may be responsible for some cases, it remains an extremely rare cause of uveitis. False-positive serologies have been found in patients with intraocular inflammatory syndromes caused by sarcoid, Behçet's disease, Vogt-Koyanagi-Harada syndrome, Reiter's syndrome, and *Propionibacterium acnes* (17,19). It has therefore been recommended that Lyme serologies not

be obtained routinely for patients with uveitic syndromes in nonendemic areas (17,19,68,78).

Neuroretinitis. The etiology of neuroretinitis, like uveitis, often remains elusive despite extensive testing. Patients with neuroretinitis and Lyme disease have also been described (16,17,40,57,79–83) as demonstrating rapid improvement after treatment with i.v. Ceftriaxone (83). Because neuroretinitis usually resolves without therapy, a causal relationship is difficult to prove on the basis of response to antibiotic treatment (16,17).

Choroiditis. Chorioditis with exudative retinal detachment has been reported in association with Lyme meningitis in two cases, both of which improved dramatically after doxycycline therapy (43,56,64). Because choroiditis may represent a nonspecific immunologic reaction to one of many infectious agents, it is difficult to interpret the etiologic basis in any specific case. Examples of choroidal inflammation, including multifocal choroiditis, birdshot chorioretinopathy, serpiginous choroiditis, pigment epitheliopathy, and acute multifocal placoid pigment epitheliopathy have been described in patients with positive Lyme serologies (63,79,80,84–87), but a causal relationship often has not been established (17). On the other hand, the microscopic evidence of *B. burgdorferi* found by Schubert et al. (76) is additional proof that the eye is a potentially immunologically sequestered site, where a local immunologic response may occur in late Lyme disease. A retinal vasculitis, similar to that seen in the later stages of syphilis (35), has been described in several cases of Lyme disease associated with vitritis and pars planitis (35,41,43,56). One of these patients with a positive *B. burgdorferi* serology improved markedly with tetracycline treatment. In their review of retinal vasculitis in Lyme borreliosis, Smith and colleagues (35) refer to a case described by Brogan et al. (88) of cerebral vasculitis in a postpartum woman with a positive cerebrospinal fluid (CSF) Lyme titer; however, the possibility of peripartum eclampsia cannot be excluded in this case (89).

Orbital Inflammation

One case of orbital inflammation was described by Seidenberg and Leib (55) and attributed to Lyme disease. A 5-year-old child presented with orbital pain, proptosis, and diplopia 6 months after an EM-like rash. A computed tomography (CT) scan of the orbits demonstrated enlargement of the medial and inferior rectus muscles, consistent with orbital myositis. The signs and symptoms resolved completely following corticosteroid therapy (41,55); however, as noted in previous reviews (16,17), the patient was examined and treated before the development of serologic testing for *B. burgdorferi* infection, and Lyme disease was a retrospective diagnosis in this case. The pathogenetic mechanism suggested by Atlas et al. in a description of Lyme myositis in the skeletal muscle is borrelial invasion of muscle and subsequent immune reaction (90).

Pupillary Abnormalities

Three cases of pupillary abnormalities in patients with early disseminated Lyme disease have been reported (38, 41,57,91). Argyll-Robertson pupils were briefly mentioned in a report by Reik et al. (38) on neurologic abnormalities in Lyme disease; the occurrence of a tonic pupil has been described in a report of other neuro-ophthalmologic manifestations (57). Glauser et al. (91) reported a 30-year-old man with a history of tick bite, EM, and flu-like symptoms beginning 4 days before presentation with a left Horner's syndrome. Although Lyme serologies were negative at the time of initial evaluation, titers were markedly positive 2 weeks later. The anisocoria resolved following a 10-day course of i.v. Ceftriaxone. Chest radiographs and magnetic resonance imaging (MRI) studies of the brain and spine did not reveal any other probable cause for the Horner's syndrome. The authors have encountered two other patients with Horner's syndrome as an early manifestation of Lyme disease. One patient developed EM 1 week after the oculosympathetic paresis was noted; the other patient had a concomitant EM rash (Fig. 2).

Optic Nerve Dysfunction

Papilledema, which occurs in association with Lyme meningitis and meningoencephalitis, is a frequent neuro-ophthalmic manifestation of Lyme disease (38,41,57,85–87,92–98), especially in children (41,99). Increased intracranial pressure (99–101) and transient visual obscurations (96) have been misinterpreted as "pseudotumor cerebri"; however, diagnosis of pseudotumor cerebri requires normal CSF and neuroimaging; review of CSF

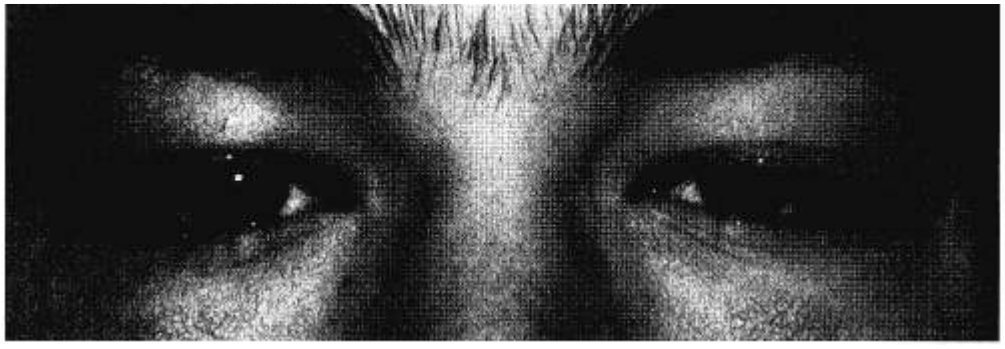

FIG. 2. Patient with left Horner's syndrome and early Lyme disease. Two erythema migrans lesions were present on the leg. (Photograph courtesy of David Roby, M.D.)

profiles in these three children with optic disc swelling and increased intracranial pressure revealed elevated protein and lymphocytosis consistent with meningitis (16,17,93,94). Belman et al. (99) reviewed the neurologic manifestations of Lyme disease in 96 children; of six patients with papilledema and documented increased intracranial pressure, all demonstrated a CSF pleocytosis, elevated CSF protein, or both.

Optic atrophy also has been reported as a possible sequela of *B. burgdorferi* infection (36,38,49,58,59,102, 103); this manifestation occurs most likely as a consequence of papilledema and meningitis rather than an end-result of ischemic or inflammatory optic neuropathy (16,17).

In patients with early disseminated Lyme disease, disc swelling has been observed and interpreted as "optic neuritis" (25,40,41,45,57,104–109), or "anterior ischemic optic neuropathy" (41,102,110,111) and even "temporal arteritis," depending on the age of the patient. Although optic neuritis has been reported in the United States and Europe (25,40,45,57,96,106,108,112) in patients with other neurologic findings or with positive Lyme serologies, definitive evidence has not been demonstrated of a causal relationship with *B. burgdorferi* infection or of dramatic or rapid improvement of visual acuity or resolution of afferent pupillary defect with antibiotic treatment in these cases (16,17,19,57,100,111). For example, Farris and Webb (32) described a patient with "Lyme optic neuritis," who was from a nonendemic area and had a serum positive for MHATP and FTA-ABS as well as a positive Lyme IgM ELISA, consistent with either coexisting syphilis and Lyme disease or a false-positive Lyme serology in the setting of syphilis alone (21,22,31,32).

The tendency to overdiagnose Lyme disease is typified by a study in which serum antibodies to *B. burgdorferi* were measured by ELISA in patients with newly diagnosed optic neuritis in the highly endemic areas of northern and central Wisconsin (109). The seropositivity rates of the asymptomatic population in this geographic area is between 10 and 20% (113,114). Nevertheless, the authors reported that four of 20 consecutive patients had positive Lyme serologies, three of them demonstrated rising convalescent IgM titers, and two had CSF lymphocytosis. All four seropositive patients exhibited improvement of visual acuity after antibiotic treatment. Indeed, the significance of this result must at least be tempered with the knowledge of the natural history of optic neuritis, from which spontaneous improvement is the rule. Studies comparing Lyme antibody titers in patients with multiple sclerosis with those of controls revealed similarly low frequencies of seropositivity in both groups, discounting previous hypotheses that *B. burgdorferi* infection could be an etiologic factor in multiple sclerosis (26,45,104,105).

A more convincing case of optic neuritis has been described by Strominger et al. (115) in a patient with other well-described manifestations of Lyme disease and positive lymphoproliferative response to *B. burgdorferi* (95% specific) and CSF PCR analysis. This patient exhibited a transient worsening of her optic neuropathy in the setting of a Jarisch-Herxheimer reaction (see Treatment) and also demonstrated improvement with Ceftriaxone therapy. Although no evidence of demyelineating disease or other inflammatory disorder has been found in this patient after 4 years of follow-up, most cases of optic neuritis that occur in patients with Lyme seropositivity remain idiopathic or are associated with underlying demyelinating disease, which may not achieve diagnosis for 10 to 15 years after initial presentation of optic neuritis (116). Long-term follow-up is necessary to determine whether patients with optic neuritis and positive Lyme serologies will eventually develop demyelinating disease consistent with multiple sclerosis (16,17). Lesser (40) has recommended that routine screening for Lyme disease not be performed in cases of optic neuritis in the absence of suggestive clinical history. The presence of antibodies to *B. burgdorferi* in spinal fluid may be useful in distinguishing Lyme-associated optic neuritis or encephalomyelitis from that of postviral demyelination or multiple sclerosis (38,95).

Definite causation also remains unproven in cases of anterior ischemic optic neuropathy (AION) (16,17,34,35, 38,70,99,110,111). In 1986, Schechter (110) described a 53-year-old patient with sequential anterior ischemic optic neuropathies 4 months after an EM-like rash and flu-like symptoms. He also had developed fever, myalgias, and a sensorimotor polyradiculopathy 3 months before the first episode of AION. The sedimentation rate was elevated at 70 mm/h, but a temporal artery biopsy was negative, and visual loss in the fellow eye subsequently developed despite treatment with high-dose steroids; however, other vasculitides could not be excluded based on available data in the case report, and whether or not the patient was treated for hypertension also was not indicated. Another case of AION after a tick bite and EM was reported by Pizzarello et al. (111). This 71-year-old patient had biopsy-proven giant cell arteritis, with characteristic multinucleated giant cells in the temporal artery specimens. Although a silver stain was interpreted as showing spirochetes within the multinucleated giant cells, the patient had negative Lyme serologies (16,111).

Meningitis and Cranial Neuropathies

Neurologic manifestations of Lyme disease during the early disseminated phase comprise a characteristic clinical triad of meningitis, cranial neuritis, and radiculoneuritis, which has been well-described and studied (4,26, 37,96,107,117–119). Four weeks after the initial infection with *B. burgdorferi*, indicated by tick bite and EM, about 15% of patients with Lyme disease develop an aseptic meningitis with symptoms including severe headache, nausea, vomiting, photophobia, stiff neck, fever, and fatigue (4,26,100,118). Papilledema may also occur as described above. Characteristic features of the CSF include normal glucose but mildly elevated protein, and a lymphocytic or plasma cell pleocytosis of about 100 cells per cubic millimeter (4,100,103,118,120–122). This CSF profile of aseptic meningitis is not specific for

Lyme disease, however, and its differential diagnosis includes syphilis, leptospirosis, sarcoid, tuberculosis, vasculitis, collagen vascular disease, and demyelinating disease, all of which must be considered, even in areas endemic for Lyme disease (16,17,100).

B. burgdorferi has been successfully cultured from spinal fluid, confirming direct invasion of the CSF by spirochetes (4,123,124); however, culture of the spirochete from patients is extremely difficult (26,125) and is not routinely attempted for diagnostic purposes. Specific IgG or IgM antibodies to *B. burgdorferi* are produced intrathecally (4,126), and their assay is considered to be diagnostic and highly specific for neurologic involvement in Lyme disease (26,37,127). The sensitivity of intrathecal antibody production in the setting of meningitis is about 90% (26,128–130); however, the absence of high antibody titers in the CSF does not entirely exclude *B. burgdorferi* infection (38,131,132); and PCR analysis of CSF for *B. burgdorferi* antigens also is often positive in patients with Lyme meningitis (26,133). Oligoclonal bands can be present in the spinal fluid of patients with Lyme disease (4,134), adding to diagnostic uncertainty between multiple sclerosis and Lyme disease, but myelin basic protein has not been found (4,135).

Cranial neuropathies usually accompany Lyme meningitis (26,37,96,118,119,127). Of particular neuro-ophthalmic importance, cranial nerves III, IV, VI, and VII may be involved individually or in combination during the course of disseminated *B. burgdorferi* infection (98,108,117,128–130,136).

Unilateral or bilateral peripheral facial (VIIth) nerve palsy (Fig. 3) is the most common cranial neuropathy associated with Lyme disease (4,100,103,108,118,137). Facial nerve palsy may accompany meningitis, it may be the initial presenting sign of Lyme disease preceding meningitis, or it may even occur in the absence of meningitis as the only neurologic manifestation (4,100,137). Facial palsy develops in as many as 50% of cases of Lyme meningitis, according to a report of 38 patients by Pachner and Steere (118); one third of these patients had bilateral involvement. In a prospective study by Halperin et al. (138), eight of 32 patients who presented with isolated "Bell's palsy" in Suffolk County on Long Island, a New York area highly endemic for Lyme disease, had a positive Lyme ELISA, suggesting that Lyme disease may be associated with as many as 25% of cases of newly diagnosed VIIth nerve palsy in a highly endemic area. The authors urged caution in the routine prescription of corticosteroids for idiopathic Bell's palsy, as studies of a small number of patients by Dattwyler et al. (139,140) suggested that steroids may adversely affect the outcome of antibiotic treatment for *B. burgdorferi* infection. Nonetheless, Lyme disease is an infrequent cause of isolated facial nerve palsy; other infectious, inflammatory, neoplastic, and ischemic causes must be considered in the differential diagnosis (17,141).

Ocular motility disorders are uncommon in Lyme disease but occasionally manifest as abducens (VIth) nerve palsies (40,57,118), and rare oculomotor (IIIrd) and trochlear (IVth) nerve involvement (Fig. 4) have been documented in the neurologic and ophthalmologic literature (25,36,38,47,57,100,103,108,117,118,127,142). Purported mechanisms for cranial neuropathies associated with Lyme disease include local inflammation in the subarachnoid space, as in meningitis; mononeuritis multiplex with vasculitis or direct invasion of the nerve by spirochetes; or, in the case of VIth nerve palsy, increased intracranial pressure (40,57,118).

In addition to the above mechanisms, an immunologic pathogenesis has been proposed in the case of a 40-year-old man who developed an isolated fascicular abducens palsy 3 months after a tick bite, EM, and flu-like symptoms (143). Serum Lyme capture ELISA antibody titers were markedly positive, and there was evidence of intrathecal IgG antibody production (CSF/serum IgG ratio 11:3;normal <1) without a lymphocytic pleocytosis. An MRI of the brain demonstrated an isolated area of hyperintensity on T2-weighted images at the left pontomedullary junction. The VIth nerve palsy, which had developed after a 1-month course of oral doxycycline, did not respond to i.v. Ceftriaxone therapy but improved markedly after a 4-week prednisone taper. One of us (J.M.S.W.) has seen two cases of recurrent painful cranial neuropathy involving III, IV, V, and VI, with nondiagnostic MRI, and in the absence of etiologic diagnosis, labeled Tolosa-Hunt syndrome. In each case, CSF showed pleocytosis with benign lymphocytes and positive Lyme ELISA. In one case, the symptoms resolved after antibiotic and steroid therapy. The second patient was a 60-year-old diabetic woman in whom an equivocal serum Lyme titer was disregarded initially and the symptoms diminished untreated. A year later, the patient returned with involvement of cranial nerves IX, X, XII on the other side, negative neuroimaging, and CSF positive for Lyme disease. After antibiotic treatment consisting of 6 weeks of i.v. Ceftriaxone, slow resolution was seen, but a year later she returned with bilateral VIth and VIIth nerve pareses, which improved on steroids. In an endemic area for Lyme disease, such cases are assumed to represent some chronic complex immunologic reaction to *B. burgdorferi*, but the final diagnosis is awaited with skepticism. Although the precise role of immunologic factors in the development of CNS Lyme disease remains uncertain (144), *B. burgdorferi* proteins do share antigenic properties with human nerve cells and axons (145), and immune mechanisms are thought to play an important role in the pathogenesis of late Lyme disease manifestations (4).

NEUROLOGIC MANIFESTATIONS

Similar to cranial neuropathies, painful radiculoneuritis may occur in the setting of meningitis and is a well-recognized manifestation of early disseminated *B. burgdorferi* infection (16,17,26,37,96,118,119,128,146–150). Intrathecal antibody production may be present in up to 90% of such patients when meningitis is present (26,119, 128–130), and PCR is often positive (26,133). Lyme-

FIG. 3. Patient with Lyme disease and multiple cranial neuropathies, including right IVth, Vth, and VIIth nerve palsies. **A:** Photograph demonstrating right facial palsy. **B:** Note aberrant regeneration of the right VIIth nerve with contraction of the orbicularis oculi on attempted smile. **C:** Gadolinium-enhanced T_1-weighted magnetic resonance image of the same patient demonstrating enlargement and enhancement of the right Vth nerve (arrow).

associated radiculoneuritis may manifest as thoracic sensory radiculitis, motor radiculoneuritis in the extremities, mononeuritis, mononeuritis multiplex, or brachial plexitis (118,119,150). Lancinating radicular pain is often localized to the dermatome where the tick bite occurred (119,148,149). These peripheral nervous system manifestations of early infection should be distinguished from the chronic sensorimotor polyneuropathy associated with late Lyme disease (see below).

A mild encephalitis has also been described during the early disseminated phase of Lyme disease, often in association with meningitis (16,17,26,38,95,102,103,107, 118,120,128). In most cases, the encephalopathy is self-limited and characterized by lethargy, memory loss, and emotional lability (17,38,128). Rarely, patients with focal encephalitis in this setting have been reported with seizures, ataxia, hemiparesis, and chorea (16,17,100, 106).

A

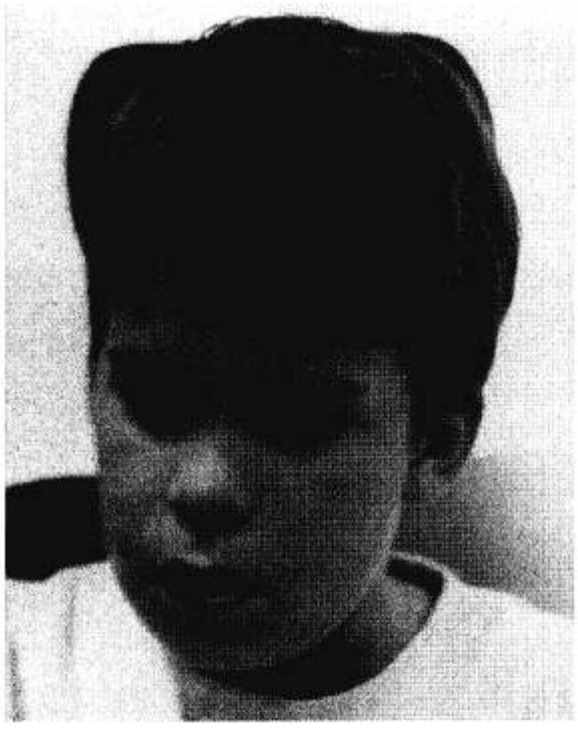

B

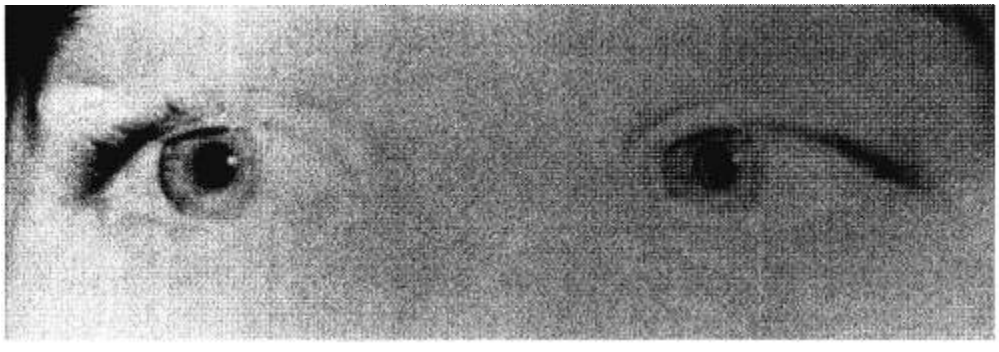

FIG. 4. A: Photograph of a young boy with Lyme meningitis and right IVth and VIth nerve palsies. Prominent head tilt and face turn were present in primary gaze. **B:** Note the right abduction deficit in attempted right gaze. (Photographs courtesy of Grant Liu, M.D.)

Late Lyme disease is also characterized by neurologic manifestations that have been well documented (16,17, 26,98,127,128,151). Peripheral polyneuropathy, encephalopathy, and, rarely, leukoencephalomyelitis (17,26) may occur months to years after the initial infection (98). Unlike the radiculoneuritis of early disseminated infection, chronic polyneuropathy of late Lyme disease typically is not associated with meningitis or intrathecal antibody production (26). The underlying pattern of peripheral nerve involvement is consistent with a mononeuropathy multiplex, and electrodiagnostic features are similar to those of early radiculoneuritis (26,37,147,152). In a 1996 review of practice parameters, Halperin et al. (26) urged caution in the diagnosis of Lyme disease-associated peripheral neuropathy, as vasculitic processes presenting as mononeuropathy multiplex may cause false elevations in *B. burgdorferi* antibody titers.

The encephalopathy of late Lyme disease is characterized by mild confusion, memory impairment, attention deficits, headache, fatigue, and depression (17,26,37,98, 153,154,155). These signs and symptoms have been demonstrated in patients with a history of typical *B. burgdorferi* infection, suggesting a causal relationship (26). Spinal fluid, electroencephalography, and MRI examinations are usually unrevealing at this stage (26). Consequently, some authors have suggested that systemic infection outside the CNS may be an indirect cause of the encephalopathy (20,26,156). Nonetheless, some patients may respond to antibiotic treatment (26).

A rare syndrome of progressive or monophasic leukoencephalomyelitis has also been described as a late manifestation of Lyme disease (16,17,26,38,95,102,127, 157). The combination of focal signs and symptoms (ataxia, sensory loss, hemiparesis) and unifocal or multifocal white matter lesions on MRI may produce a clinical picture that mimics multiple sclerosis (17,26). As outlined by Halperin et al. (26), however, there is convincing evidence against a causal relationship between *B. burgdorferi* infection and multiple sclerosis (102,104, 105,128). Winterkorn (17) recently outlined criteria that may be helpful for distinguishing Lyme encephalomyelitis from MS in a seropositive patient. Based on recent

studies (20,98,128,155), these criteria include a history indicative of acute Lyme disease, intrathecal antibody production, and dramatic response to i.v. Ceftriaxone (17). The possibility of misdiagnosis is greatly increased when one relies solely on the presence of a positive serum Lyme titer. In the authors' collective experience, multiple sclerosis is the most common neuro-ophthalmic disorder mistaken for Lyme disease. These patients have demonstrated more favorable responses to corticosteroids than to antibiotics.

PREVENTION AND TREATMENT

The issues of prevention of and personal protection against Lyme disease have been emphasized in the recent literature (6,14,22). In high-risk areas, Stanford (158) suggested such personal protection strategies as wearing light-colored clothing to make ticks visible, tucking pant cuffs into socks and using tick or insect repellents such as those containing permethrin (applied to clothing) or DEET (*N,N*-diethyl-*m*-toluamide) (applied to exposed skin). In addition, Fish (6) emphasizes the importance of daily inspections for attached ticks following outdoor activities and the immediate removal of ticks with sharply pointed forceps. Data from animal studies by Piesman et al. (159) suggest that transmission of *B. burgdorferi* increases with the length of time the tick remains attached and that the maximum efficiency of transmission does not occur until after 48 h. Some pediatricians recommend daily immersion in water for 5 to 10 min by bathing or swimming to interrupt the extended blood meal, but controlled studies in this regard are not available.

Oral antibiotic therapy shortens the duration of the EM rash and prevents the development of late sequelae of Lyme disease in most patients (22). Despite the recognition that inadequate early treatment of Lyme disease may increase the likelihood of late manifestations and lead to relapses, the duration of treatment has not been well established for any manifestation or clinical stage of Lyme disease (4,17,22,23,26).

Whereas oral antibiotics are indicated for EM or early Lyme disease, treatment for ocular and neurologic manifestations should include, in most cases, i.v. antibiotic therapy (4,16,17,22,23,26,32); however, oral therapy may be appropriate in patients with isolated unilateral peripheral VIIth nerve palsy without cerebrospinal fluid abnormalities (4,22,23,26,32). Table 1 has been constructed based on recent literature outlining current treatment recommendations (4,22,23,26,32).

For all antibiotic regimens, treatment failures and relapses have been reported (22,23); however, most cases should be effectively treated by a single course of antibiotics (17). Additional or prolonged courses of therapy are not recommended, and treatment failure should prompt a reconsideration of the underlying diagnosis (20).

About 14% of patients with Lyme disease experience a worsening of symptoms within the first 24 h of treatment, which can be attributed to the Jarisch-Herxheimer reaction, a recognized complication of the treatment of

TABLE 1. *Treatment of Lyme disease*

	Drug	Dosages[b]
Erythema migrans/flu-like symptoms[a]		
First line	Doxycycline[c]	Adult: 100 mg p.o. b.i.d. Pediatric: 2–4 mg p.o./kg/day divided b.i.d.[c]
	Amoxicillin	Adult: 500 mg p.o. t.i.d. Pediatric: 40–50 mg p.o./kg/day divided t.i.d.
Alternatives	Phenoxymethyl penicillin	Adult: 500 mg p.o. q.i.d. Pediatric: 50 mg p.o/kg/day divided t.i.d.–q.i.d.
	Tetracycline[c]	Adult: 500 mg p.o. q.i.d. Pediatric: 25–50 mg p.o./kg/day divided q.i.d.[c]
	Cefuroxime axetil	Adult: 500 mg p.o. b.i.d. Pediatric: 30 mg p.o./kg/day divided b.i.d.
Second line[d]	Erythromycin	Adult: 500 mg p.o. q.i.d. Pediatric: 30–40 mg p.o./kg/day divided q.i.d.
	Azithromycin	Adult: 500 mg p.o. daily for *5–10 days* Pediatric: not recommended for children <16 yr
Neurologic or ophthalmic disease[e]		
First line	Ceftriaxone	Adult: 2 g i.v. daily Pediatric: 75–100 mg i.v./kg/day
	Penicillin G	Adult: 20–24 million units i.v./day divided q 4 h Pediatric: 300,000 U i.v./kg/day divided q 4 h
Alternatives	Doxycycline[c]	Adult: 100 mg p.o. or i.v. b.i.d. Pediatric: 2–4 mg p.o. or i.v./kg/day divided b.i.d.[c]
	Chloramphenicol	Adult: 50 mg i.v./kg/day divided q 6 h Pediatric: 50 mg i.v./kg/day divided q 6 h

[a] Recommended duration of therapy, 10 to 30 days (22).
[b] Pediatric dosages should not exceed adult dosages.
[c] *Not* recommended for children aged <9 years or during pregnancy or lactation.
[d] May not be as effective as other agents.
[e] Recommended duration of therapy, 14 to 30 days (22).

spirochetal infections that is characterized by hypotension, chills, fever, arthralgias, and myalgias (115). Symptoms of the Jarisch-Herxheimer reaction usually resolve within 72 h and may be treated with anti-inflammatory agents, such as aspirin or corticosteroids. The use of systemic corticosteroids otherwise during the course of Lyme disease is controversial (4,26,32). In a small number of patients previously treated with corticosteroids, Dattwyler et al. (139,140) reported a high incidence of antibiotic treatment failure, suggesting that systemic corticosteroids should be avoided in the setting of early infection.

Antimicrobial prophylaxis for tick bites in an endemic area before the appearance of EM or other signs or symptoms also has not been supported convincingly by data from clinical trials (4,22,32,160). Because the treatment of early Lyme disease is effective and generally prevents the occurrence of late manifestations, routine administration of antibiotics after *Ixodes* tick bites is not recommended (22,32). Such treatment decisions must also weigh the duration of tick attachment, the species of tick, and the tick infectivity rate for that region. The issue of whether and how asymptomatic *B. burgdorferi* infection should be treated remains unresolved (4).

CONCLUSION

Lyme disease is a multisystem infection caused by the tick-borne spirochete, *Borrelia burgdorferi*. The North American form of Lyme disease was first described in the United States 20 years ago. Since then, numerous neuro-ophthalmic signs and symptoms have been attributed to *B. burgdorferi* infection, but few have been definitely proved. In endemic regions, a causal relationship with Lyme disease has been most convincingly demonstrated in patients with neurologic manifestations and a positive CSF serology and in patients with certain types of intraocular inflammation, including keratitis. Clinical judgment must be used in deciding whether or not to treat individual patients. In cases where neurologic symptoms are accompanied by convincing clinical or laboratory evidence of Lyme disease, treatment of reasonable duration may be warranted despite difficulty in establishing a definite causal relationship (26).

REFERENCES

1. Steere AC, Malawista SE, Snydman DR, et al. Lyme arthritis: an epidemic of oligoarticular arthritis in children and adults in three Connecticut communities. *Arthritis Rheum* 1977;20:7–17.
2. Burgdorfer W, Barbour AG, Hayes SF, et al. Lyme disease—a tick-borne spirochetosis? *Science* 1982;216:1317–9.
3. Johnson RC, Schmid GP, Hyde FW, Steigerwalt AG, Brenner DJ. *Borrelia burgdorferi* sp. nov.: etiologic agent of Lyme disease. *Int J Syst Bacteriol* 1984;34:496–7.
4. Steere AC. Lyme disease. *N Engl J Med* 1989;321:586–96.
5. Barbour AG, Fish D. The biological and social phenomenon of Lyme disease. *Science* 1993;260:1610–6.
6. Fish D. Environmental risk and prevention of Lyme disease. *Am J Med* 1995;98(suppl 4A):2S–14S.
7. Levine JF, Wilson ML, Spielman A. Mice as reservoirs of the Lyme disease spirochete. *Am J Trop Med J Hyg* 1985;34:355–60.
8. White DJ, Chang HG, Benach JL, et al. The geographic spread and temporal increase of the Lyme disease epidemic. *JAMA* 1991;266:1230–6.
9. Duffy DC, Campbell SR, Clark D, DiMotta C, Gurney S. *Ixodes scapularis* (Acari: Ixodidae) deer tick mesocale populations in natural areas: effects of deer, area, and location. *J Med Entomol* 1994;31:152–8.
10. Wilson ML, Adler GH, Spielman A. Correlation between abundance of deer and that of the deer tick, *Ixodes dammini* (Acari: Ixodidae) following elimination of deer. *Ann Entomol Soc Am* 1985;78:172–6.
11. Telford SR III, Mather TN, Moore SI, Wilson ML, Spielman A. Incompetence of deer as reservoirs of the Lyme disease spirochete. *Am J Trop Med Hyg* 1988;39:105–9.
12. Anderson JF. *Borrelia burgdorferi* and *Ixodes dammini* prevalence in the greater Philadelphia area. *J Infect Dis* 1990;161: 811–2.
13. Fish D. Population ecology of *Ixodes dammini*. In: Ginsberg HS, ed. *Ecology and Environmental Management of Lyme Disease.* New Brunswick, NJ: Rutgers University Press, 1993:25–42.
14. CDC. Lyme disease—United States, 1995. *MMWR* 1996;45: 481–4.
15. CDC. Lyme disease—United States, 1993. *MMWR* 1993;43:564–72.
16. Winterkorn JMS. Lyme disease: neurologic and ophthalmic manifestations. *Surv Ophthalmol* 1990;35:191–204.
17. Winterkorn JMS. Neuro-ophthalmic Lyme disease in perspective. In: Tusa RJ, Newman SA, eds. *Neuro-ophthalmic Disorders: diagnostic work-up and management.* New York, NY: Dekker, 1995:561–82.
18. Winterkorn JMS. Lyme disease? *Arch Ophthalmol* 1992;110:794.
19. Winterkorn JMS. Putting Lyme disease in perspective. *Rev Ophthalmol* 1995;2:74–80.
20. Steere AC, Taylor E, McHugh GL, et al. The overdiagnosis of Lyme disease. *JAMA* 1993;269:1812–6.
21. Coyle PK. Lyme disease. In: Feldman E, ed. *Current diagnosis in neurology.* St. Louis, MO: Mosby-Year Book, Inc., 1994: 110–4.
22. Treatment of Lyme disease. In: Abramowicz M, ed. *The medical letter on drugs and therapeutics.* New Rochelle, NY: The Medical Letter, Inc., 1992:95–7.
23. Nadelman RB, Wormser GP. Erythema migrans and early Lyme disease. *Am J Med* 1995;98(suppl 4A):15S–24S.
24. Malane MS, Grant-hels JM, Feder HM, Jr., Luger SW. Diagnosis of Lyme disease based on dermatologic manifestations. *Ann Intern Med* 1991;114:490–8.
25. MacDonald AB. Lyme disease: a neuro-ophthalmologic view. *Neuro-ophthalmol* 1987;7:185–90.
26. Halperin JJ, Logigian EL, Finkel MF, Pearl RA. Practice parameters for the diagnosis of patients with nervous system Lyme borreliosis (Lyme disease). *Neurology* 1996;46:619–27, 881–2.
27. Karlsson M, Hovind HK, Svenungsson B, Stiernstedt G. Cultivation and characterization of spirochetes from cerebrospinal fluid of patients with Lyme borreliosis. *J Clin Microbiol* 1990; 28:473–9.
28. Steere AC, Duray PH, Kauffmann DJH, Wormser GP. Unilateral blindness caused by infection with the Lyme spirochete, *Borrelia burgdorferi*. *Ann Intern Med* 1985;103:382–5.
29. Duray PH. The surgical pathology of human Lyme disease: an enlarging picture. *Am J Surg Pathol* 1987;11:47–60.
30. CDC. Recommendations for test performance and interpretation from the Second National Conference on Serologic Diagnosis of Lyme disease. *MMWR* 1995;44:590–1.
31. Magnarelli LA. Current status of laboratory diagnosis for Lyme disease. *Am J Med* 1995;98(suppl 4A):10S–4S.
32. Rahn DW, Malawista SE. Lyme disease: recommendations for diagnosis and treatment. *Ann Intern Med* 1991;114:472–81.
33. Steere AC, Berardi VP, Weeks KE, Logigian EL, Ackermann R. Evaluation of the intrathecal antibody response to *Borrelia burgdorferi* as a diagnostic test for Lyme neuroborreliosis. *J Infect Dis* 1990;161:1203–9.
34. Smith JL, Parsons TM, Paris-Hamelin AJ, et al. The prevalence of Lyme disease in a nonendemic area. *J Clin Neuro-ophthalmol* 1989;9:148–55.

35. Smith JL, Winward KE, Nicholson DF, Albert DW. Retinal vasculitis in Lyme borreliosis. *J Clin Neuro-ophthalmol* 1991;11:7–15.
36. Winward KE, Smith JL, Culbertson WW, Paris-Hamelin A. Ocular Lyme borreliosis. *Am J Ophthalmol* 1989;108:651–7.
37. Halperin JJ, Pass HL, Anand AK, Luft BJ, Volkman DJ, Dattwyler RJ. Nervous system abnormalities in Lyme disease. *Ann NY Acad Sci* 1988;539:24–34.
38. Reik L, Burgdorfer W, Donaldson JO. Neurologic abnormalities in Lyme disease without erythema chronicum migrans. *Am J Med* 1986;81:73–8.
39. Ciesielski CA, Markowitz LE, Horsely R, Hightower AW, Russell H, Broome CV. The geographic distribution of Lyme disease in the United States. *Ann NY Acad Sci* 1988;539:283–8.
40. Lesser RL. Ocular manifestations of Lyme disease. *Am J Med* 1995;98(suppl 4A):60S–2S.
41. Bergloff J, Gasser R, Feigl B. Ophthalmic manifestations in Lyme borreliosis. *J Neuro-ophthalmol* 1994;14:15–20.
42. Mombaerts IM, Maudgal PC, Knockaert D. Bilateral follicular conjunctivitis as a manifestation of Lyme disease. *Am J Ophthalmol* 1991;112:96–7.
43. Bialasiewicz AA. Augenbefunde bei Lyme-Borreliose. *Ophthalmologe* 1992;89:W47–59.
44. Steere AC, Bartenhagen NH, Craft JE, et al. The early clinical manifestations of Lyme disease. *Ann Intern Med* 1983;99:76–82.
45. Farris BK, Webb RM. Lyme disease and optic neuritis. *J Clin Neuro-ophthalmol* 1988;8:73–8.
46. Breeveld J, Rothova A, Kuiper H. Intermediate uveitis and Lyme borreliosis. *Br J Ophthalmol* 1992;76:181–2.
47. Flach AJ, Lavoie PE. Episcleritis, conjunctivitis, and keratitis as ocular manifestations of Lyme disease. *Ophthalmology* 1990;97:973–5.
48. Baum J, Barza M, Weinstein P, et al. Bilateral keratitis as a manifestation of Lyme disease. *Am J Ophthalmol* 1988;105:75–7.
49. Bertuch AW, Rocco E, Schwartz EG. Lyme disease: ocular manifestations. *Ann Ophthalmol* 1988;20:376–8.
50. Zaidman GW. Episcleritis and symblepharon associated with Lyme keratitis. *Am J Ophthalmol* 1990;109:487–8.
51. Orlin SE, Lauffer JL. Lyme disease keratitis. *Am J Ophthalmol* 1989;107:678–9.
52. Kornmehl EW, Lesser RL, Jaros P, Rocco E, Steere AC. Bilateral keratitis in Lyme disease. *Ophthalmology* 1989;96:1194–7.
53. Szer IS, Taylor E, Steere AC. The long term course of Lyme arthritis in children. *N Engl J Med* 1991;325:159–63.
54. Fox GM, Heilskov T, Smith JL. Cogan's syndrome and seroreactivity to Lyme borreliosis. *J Clin Neuro-ophthalmol* 1990;10:83–7.
55. Seidenberg KB, Leib ML. Orbital myositis with Lyme disease. *Am J Ophthalmol* 1990;109:13–6.
56. Fukiawa LS. Advances in immunology and uveitis. *Ophthalmology* 1989;96:1115–20.
57. Lesser RL, Kornmehl EW, Pachner AR, et al. Neuro-ophthalmologic manifestations of Lyme disease. *Ophthalmology* 1990;97:699–706.
58. Bertuch AW, Rocco E, Schwartz EG. Eye findings in Lyme disease. *Conn Med* 1987;51:151–2.
59. Kauffmann DJH, Wormser GP. Ocular Lyme disease: case report and review of the literature. *Br J Ophthalmol* 1990;74:325–7.
60. deLuise VP, O'Leary MI. Peripheral ulcerative keratitis related to Lyme disease [Letter]. *Am J Ophthalmol* 1991;111:244–5.
61. Wokke JHJ, VanGijn J, Elderson A, Stanek G. Chronic forms of *Borrelia burgdorferi* infections of the nervous system. *Neurology* 1987;37:1031–4.
62. Eichenfeld AH, Goldsmith DP, Benach JL, et al. Childhood Lyme arthritis: experience in an endemic area. *Pediatrics* 1986;109:753–8.
63. Suttorp-Schulten MSA, Luyendijk L, van Dam AP, et al. Birdshot chorioretinopathy and Lyme borreliosis. *Am J Ophthalmol* 1993;115:149–53.
64. Bialasiewicz AA, Ruprecht KW, Naumann GOH, Blenk H. Bilateral diffuse choroiditis and exudative retinal detachments with evidence of Lyme disease. *Am J Ophthalmol* 1988;105:419–20.
65. Smith JL. Neuro-ocular Lyme borreliosis. *Neurol Clin* 1991;9:35–53.
66. Boutros A, Rahn E, Nauheim R. Iritis and papillitis as a primary presentation of Lyme disease. *Ann Ophthalmol* 1990;22:24–5.
67. Culbertson WW, Winward K, Smith JL. Ocular Lyme borreliosis. *Fortschr Ophthalmol* 1991;88(suppl 2):439.
68. Isogai E, Isogai H, Kotake S, et al. Detection of antibodies against *Borrelia burgdorferi* in patients with uveitis. *Am J Ophthalmol* 1991;112:23–30.
69. Weigand W. Ocular findings in borreliosis—bilateral panuveitis with exudative retinal detachment. *Fortschr Ophthalmol* 1989;86:659–62.
70. Winward KE, Smith JL. Ocular disease in Caribbean patients with serologic evidence of Lyme borreliosis. *J Clin Neuro-ophthalmol* 1989;9:65–70.
71. Zierhut M, Kreissig I, Pickert A. Panuveitis with positive serological tests for syphilis and Lyme disease. *J Clin Neuro-ophthalmol* 1989;9:71–5.
72. Rothova A, Kuiper H, Spanjaaed L, Dankert J, Breebart A. Spiderweb vitritis in Lyme borreliosis. *Lancet* 1991;337:490.
73. Kuiper H, Koelman JH, Jager MJ. Vitreous clouding associated with Lyme borreliosis. *Am J Ophthalmol* 1989;108:453–4.
74. Johnson RC, Marek N, Kodner C. Infection of Syrian hamsters with Lyme disease spirochetes. *J Clin Microbiol* 1984;20:1099–101.
75. Duray PH, Johnson RC. The histopathology of experimentally infected hamsters with the Lyme disease spirochete, *Borrelia burgdorferi*. *Proc Soc Exp Biol Med* 1986;181:263–9.
76. Schubert HD. Cytologically proven seronegative Lyme choroiditis and vitritis. *Retina* 1994;14:39–42.
77. Preac-Mursic B, Pfister HW, Spiegel H, et al. First isolation of *Borrelia burgdorferi* from an iris biopsy. *J Clin Neuro-ophthalmol* 1993;13:155–61.
78. Rosembaum JT, Rahn DW. Prevalence of Lyme disease among patients with uveitis. *Am J Ophthalmol* 1991;112:462–3.
79. Schonherr U, Lang GE, Meythaler FH. Bilaterale Lebersche Neuroretinitis stellata bei *Borrelia burgdorferi* serokonversion. *Klin Monatsbl Augenheilkd* 1991;198:44–7.
80. Miller NR. Case described in Walsh and Hoyt's Clinical Neuro-Ophthalmology, vol 5, 1995:3657–8. (in press).
81. Bialasiewicz AA, Huk W, Druschky KF, et al. Bilateral optic neuritis with intracranial demyelinization in a patient with *Borrelia burgdorferi* infection. *Klin Monatsbl Augenheikd* 1989;195:91–4.
82. Schonbarr U, Lang GE, Meythaler FH. Bilateral Leber's neuroretinitis stellata with *Borrelia burgdorferi* seroconversion. *Klin Monatsbl Augenheikd* 1991;198:45–7.
83. Winterkorn JS, Odel JG, Behrens MM. Presentation at Columbia-Presbyterian Medical Center/Manhattan Eye, Ear, and Throat Hospital Joint Conference, Waldorf-Astoria, NY, 1988.
84. Wilk CM, Bialasiewicz AA, Ruprecht KW, Naumann G. Bilaterale akute konfluierende choroiditis disseminata bei *Borrelia burgdorferi*-infekton. *Klin Mbl Augenheilk* 1986;194:88–96.
85. Bodine SR, Marino J, Camisa TJ, Salvate AJ. Multifocal choroiditis with evidence of Lyme disease. *Ann Ophthalmol* 1992;124:169–73.
86. Tonjes W, Mielke U, Schmidt HJ, Haass A, Holzer G. Akute multifokale plakoide pigmentepitheliopathie mit entzundlichem liquorbefund. Sonderform einer Borreliose? *Dtsch Med Wochenschr* 1989;114:793–5.
87. Wolf MD, Folk JC, Nelson JA, Peeples ME. Acute posterior multifocal placoid pigment epitheliopathy and Lyme disease. *Arch Ophthalmol* 1992;110:750.
88. Brogan GX, Homan CS, Viccellio P. The enlarging clinical spectrum of Lyme disease: Lyme cerebral vasculitis, a new disease entity. *Ann Emerg Med* 1990;19:572–6.
89. Raps EC, Galetta SL, Broderick M, Atlas SW. Delayed peripartum vasculopathy: cerebral eclampsia revisited. *Ann Neurol* 1993;33:222–5.
90. Atlas E, Novak SN, Duray PH, Steere AC. Lyme myositis: muscle invasion by *Borrelia burgdorferi*. *Ann Intern Med* 1988;109:245–6.
91. Glauser TA, Brennen PJ, Galetta SL. Reversible Horner's syn-

drome and Lyme disease. *J Clin Neuro-ophthalmol* 1989;9: 225–8.
92. Wu G, Lincoff H, Ellsworth RM, et al. Optic disc edema and Lyme disease. *Ann Ophthalmol* 1986;18:252–5.
93. Jacobson DM, Frens DB. Pseudotumor cerebri syndrome associated with Lyme disease. *Am J Ophthalmol* 1989;107:81–2.
94. Raucher HS, Kaufman DM, Goldfarb J, et al. Pseudotumor cerebri and Lyme disease: a new association. *J Pediatr* 1985;107: 931–3.
95. Bendig JW, Ogilvie D. Severe encephalopathy associated with Lyme disease. *Lancet* 1987;1:681–2.
96. Reik L, Steere AC, Bartenhagen NH, Shope RE, Malawista SE. Neurologic abnormalities of Lyme disease. *Medicine* 1979;58: 281–94.
97. Fawcett PT, Gibney KM, Rose CD, Dubbs Doughty RA. Frequency and specificity of antibodies that cross react with *Borrelia burgdorferi* antigens. *J Rheumatol* 1992;19:582–7.
98. Logigian EL, Kaplan RF, Steere AC. Chronic neurologic manifestations of Lyme disease. *N Engl J Med* 1990;324:1438–44.
99. Belman AL, Iyer M, Coyle PK, Dattwyler R. Neurologic manifestations in children with North American Lyme disease. *Neurology* 1993;43:2609–14.
100. Scully RE, Mark EG, McNeely BU. Case reports of the Massachusetts General Hospital: weekly clinicopathological exercises. *N Engl J Med* 1984;311:172–81.
101. Feder HM, Zalneraitis EL, Reik L. Lyme disease: acute focal meningoencephalitis in a child. *Pediatr* 1989;82:931–4.
102. Halperin JJ, Luft BJ, Anand AK, et al. Lyme neuroborreliosis: central nervous system manifestations. *Neurology* 1989;39: 753–9.
103. Stiernstedt G, Gustaffson R, Karlsson M, et al. Clinical manifestations and diagnosis of neuroborreliosis. *Ann NY Acad Sci* 1988; 539:46–56.
104. Coyle PK. *Borrelia burgdorferi* antibodies in multiple sclerosis. *Neurology* 1989;39:760–3.
105. Schmutzhard E, Pohl G, Stanek G. *Borrelia burgdorferi* antibodies in patients with relapsing/remitting form and chronic progressive form of multiple sclerosis. *J Neurol Neurosurg Psychiatry* 1988;41:1215–21.
106. Finkel MF. Lyme disease and its neurologic complications. *Arch Neurol* 1988;45:99–104.
107. Pachner AR. Oligoclonal bands in European Lyme disease [Reply from the Author]. *Neurology* 1985;35:1394–5.
108. Pachner AR. Spirochetal diseases of the central nervous system. *Neurol Clin* 1986;4:207–22.
109. Jacobsen DM, Marx JJ, Dlesk A. Frequency and clinical significance of Lyme seropositivity in patients with isolated optic neuritis. *Am J Ophthalmol* 1989;41:706–11.
110. Schechter SL. Lyme disease associated with optic neuropathy. *Am J Med* 1986;81:143–5.
111. Pizzarello D, MacDonald AB, Semlear R, et al. Temporal arteritis associated with *Borrelia* infection. *J Clin Neuro-ophthalmol* 1989;9:3–6.
112. Lipschutz B. Uber eine seltene Erythema chronicum migrans. *Arch Derm Syph* 1913–4;118:349–56.
113. Huycke MM, D'Alesso DD, Marx JJ. Prevalence of antibody to *Borrelia burgdorferi* by indirect fluorescent antibody assay, ELISA, and Western immunoblot in healthy adults in Wisconsin and Arizona. *J Infect Dis* 1992;165:1133–7.
114. Berger BW. Treatment of erythema chronicum migrans of Lyme disease. *Ann NY Acad Sci* 1988;539:346–51.
115. Strominger MB, Slamovits TL, Herskovitz S, Lipton RB. Transient worsening of optic neuropathy as a sequela of the Jarisch-Herxheimer reaction in the treatment of Lyme disease. *J Neuro-ophthalmol* 1994;14:77–80.
116. Rizzo JF, Lessel S. Risk of developing multiple sclerosis after uncomplicated optic neuritis. A long-term prospective study. *Neurology* 1988;38:185–90.
117. Pachner AR, Duray P, Steere AC. Central nervous system manifestations of Lyme disease. *Arch Neurol* 1989;46:790–5.
118. Pachner AR, Steere AC. The triad of neurologic manifestations of Lyme disease: meningitis, cranial neuritis and radiculoneuritis. *Neurology* 1985;35:47–53.
119. Finkel MJ, Halperin JJ. Nervous system Lyme borreliosis—revisited. *Arch Neurol* 1992;49:102–7.
120. Pachner AR. *Borrelia burgdorferi* in the nervous system: the new "great imitator." *Ann NY Acad Sci* 1988;539:56–64.
121. Steere AC, Malawista SE, Hardin JA, Ruddy S, Askenase PW, Andiman WA. Erythema chronicum migrans and Lyme arthritis: the enlarging spectrum. *Ann Intern Med* 1977;86:685–98.
122. Ackerman R, Horstrup P, Schmidt R. Tick-borne meningopolyneuritis (Garin-Bujadoux, Bannwarth). *Yale J Biol Med* 1984;57: 485–90.
123. Steere AC, Grodzicki RL, Kornblatt AN, et al. The spirochetal etiology of Lyme disease. *N Engl J Med* 1983;308:733–40.
124. Preac-Mursic V, Wilske B, Schierz G, Pfester HW, Einhaupl K. Repeated isolation of spirochetes from the cerebrospinal fluid of a patient with meningoradiculitis Bannwarth. *Eur J Clin Microbiol* 1984;3:564–5.
125. MacDonald AB. Ambiguous serologies in active Lyme Borreliosis. *J Clin Neuro-ophthalmol* 1988;8:79–80.
126. Wilske B, Schierz G, Preac-Mursic V, et al. Intrathecal production of specific antibodies against *Borrelia burgdorferi* in patients with lymphocytic meningoradiculitis (Bannwarth's syndrome). *J Infect Dis* 1986;153:304–14.
127. Ackermann R, Rehse-Kupper B, Gollmer E, Schmidt R. Chronic neurologic manifestations of erythema migrans borreliosis. *Ann NY Acad Sci* 1988;539:16–23.
128. Halperin JJ, Volkman DJ, Wu P. Central nervous system abnormalities in Lyme neuroborreliosis. *Neurology* 1991;41:1571–82.
129. Stiernstedt GT, Granstrom M, Hederstedt B, Skoldenberg B. Diagnosis of spirochetal meningitis by enzyme linked immunosorbent assay and indirect immunofluorescence assay in serum and cerebrospinal fluid. *J Clin Microbiol* 1985;21:819–25.
130. Hansen K, Lebech AM. Lyme neuroborreliosis: a new sensitive diagnostic assay for intrathecal synthesis of *Borrelia burgdorferi*—specific immunoglobulins G, A, and M. *Ann Neurol* 1991; 30:197–205.
131. Hunter EF. Evaluation of sera from patients with Lyme disease in FTA-ABS for syphilis. *Sex Transm Dis* 1986;13:232–6.
132. Neu HC. Treatment of Lyme disease. *Ann NY Acad Sci* 1988; 539:314–6.
133. Keller TJ, Halperin JJ, Whitman M. PCR detection of *Borrelia burgdorferi* DNA in cerebrospinal fluid of Lyme neuroborreliosis patients. *Neurology* 1992;42:32.
134. Henriksson A, Link H, Cruz M, Stiernstedt G. Immunoglobulin abnormalities in cerebrospinal fluid and blood over the course of lymphocytic meningoradiculitis (Bannwarth's syndrome). *Ann Neurol* 1986;20:337–45.
135. Garcia-Monco JC, Coleman JL, Benach JL. Antibodies to myelin basic protein in Lyme disease. *J Infect Dis* 1988;158:667–8.
136. Luft BJ, Steinman CR. Neimark HC, et al. Invasion of the central nervous system by *Borrelia burgdorferi* in acute disseminated infection. *JAMA* 1992;267:1364–7.
137. Clark JR, Carlson RD, Sasaki CT, et al. Facial paralysis in Lyme disease. *Laryngoscope* 1985;95:1341–5.
138. Halperin JJ, Golightly M, and the Long Island Neuroborreliosis Collaborative Study Group. Lyme borreliosis in Bell's palsy. *Neurology* 1992;42:1268–70.
139. Dattwyler RJ, Volkman DJ, Luft BJ, Halperin JJ. Lyme disease in Europe and North America. *Lancet* 1987;1:681.
140. Dattwyler RJ, Halperin JJ, Volkman DJ, Luft BJ. Treatment of late Lyme disease. *Lancet* 1988;1:1191–3.
141. Kuiper H, Devriese PP, Jongh BM, Vos K, Dankert J. Absence of Lyme borreliosis among patients with presumed Bell's palsy. *Arch Neurol* 1992;49:940–3.
142. Aaberg TM. The expanding ophthalmologic spectrum of Lyme disease. *Am J Ophthalmol* 1989;107:77–80.
143. Mastrianni JA, Galetta SL, Raps EC, Liu GT, Volpe NJ. Isolated fascicular abducens nerve palsy and Lyme disease. *J Neuro-ophthalmol* 1994;14:2–5.
144. Baig S, Olsson T, Hojeberg B, Link H. Cells secreting antibodies to myelin basic protein in cerebrospinal fluid of patients with Lyme neuroborreliosis. *Neurology* 1991;41:581–6.

145. Aberer E, Brunner C, Suchanek G, Klade H, Barbour A, Stanek G. Molecular mimicry and Lyme borreliosis: a shared antigenic determinant between *Borrelia burgdorferi* and human tissue. *Ann Neurol* 1989;26:732–7.
146. Halperin JJ. Nervous system manifestations of Lyme. *Rheum Dis Clin North Am* 1989;15:635–7.
147. Logigian EL, Steere AC. Clinical and electrophysiologic findings in chronic neuropathy of Lyme disease. *Neurology* 1992;42:303–12.
148. Garin, Bujadoux. Paralysie par les tiques. *J Med Lyon* 1922;71:765–7.
149. Bannwarth A. Chronische lymphocytäre Meningitis, entzundliche polyneuritis und 'rheumatismus.' *Arch Psychiatr Nervenkr* 1941;113:284–376.
150. Halperin JJ, Little BW, Coyle PK, Dattwyler RJ. Lyme disease: cause of a treatable peripheral neuropathy. *Neurology* 1987;37:1700–6.
151. Schmutzhard E, Stanek G, Pohl P. Polyneuritis cranialis associated with *Borrelia burgdorferi. J Neurol Neurosurg Psychiatry* 1985;18:1182–4.
152. Halperin JJ, Luft BJ, Volkman DJ, Dattwyler RJ. Lyme neuroborreliosis—peripheral nervous system manifestations. *Brain* 1990;113:1207–21.
153. Halperin JJ, Krupp LB, Golightly MG, Volkman DJ. Lyme borreliosis-associated encephalopathy. *Neurology* 1990;40:1340–3.
154. Krupp LB, Masur D, Schwartz J, et al. Cognitive functioning in late Lyme borreliosis. *Arch Neurol* 1991;48:1125–9.
155. Kaplan RF, Meadows ME, Vincent LC, Logigian EL, Steere AC. Memory impairment and depression in patients with Lyme encephalopathy: comparison with fibromyalgia and nonpsychotically depressed patients. *Neurology* 1992;42:1263–7.
156. Halperin JJ, Heyes MP. Neuroactive kynurenines in Lyme borreliosis. *Neurology* 1992;42:43–50.
157. Ackermann R, Gollmer E, Rehse KB. Progressive Borrelis encephalomyelitis: chronic manifestation of erythema chronicum migrans disease of the nervous system. *Dtsch Med Wochenschr* 1985;110:1039–42.
158. Stanford KC III. Lyme disease prevention. Personal protection and prospects for tick control. *Conn Med* 1989;53:347–51.
159. Piesman J, Mather TN, Sinsky RJ, Spielman A. Duration of tick attachment and *Borrelia burgdorferi* transmission. *J Clin Microbiol* 1987;25:557–8.
160. Costello CM, Steere AC, Pinkerton RE, Feder HM Jr. Prospective study of tick bites in an endemic area for Lyme disease. *J Infect Dis* 1989;159:136–9.