25. STEERE AC, MALAWISTA SE. Viral arthritis, In: MCCARTY DJ JR, ed. *Arthritis and Allied Conditions.* 9th ed. Philadelphia: Lea and Febiger; 1979:1391-407.
26. PETO R, PIKE MC, ARMITAGE P, et al. Design and analysis of randomized clinical trials requiring prolonged observation of each patient: I. Introduction and design. *Br J Cancer.* 1976;**34:**585-612.
27. PETO R, PIKE MC, ARMITAGE P, et al. Design and analysis of randomized clinical trials requiring prolonged observation of each patient: II. Analysis and examples. *Br J Cancer.* 1977;**35:**1-39.
28. LENNHOFF C. Spirochaetes in aetiologically obscure diseases. *Acta Derm Venereol (Stockh).* 1948;**28:**295-324.
29. HÅRD S. Erythema chronicum migrans (Afzelii) associated with mosquito bite. *Acta Derm Venereol (Stockh).* 1966;**46:**473-6.
30. DEGOS R, TOURAINE R, AROUETE J. L'erythema chronicum migrans. *Ann Dermatol Syphiligr (Paris).* 1962;**89:**247-60.
31. GIROUD P, CAPPONI M, DUMAS N. Rickettsioses et lésions cutanées en dehors de syndromes fébriles. *Bull Soc Pathol Exot.* 1962;**55:**958-62.
32. BINDER E, DOEPFMER R, HORNSTEIN O. Übertragung des Erythema chronicum migrans von Mensch zu Mensch in zwel Passagen. *Klin Wochenschr.* 1955;**33:**727-8.
33. SMILEY JD, SACHS C, ZIFF M. In vitro synthesis of immunoglobulin by rheumatoid synovial membrane. *J Clin Invest.* 1968;**47:**624-32.
34. WEINBERGER HW, ROPES MW, KULKA JP, BAUER W. Reiter's syndrome: clinical and pathologic observations: a long term study of 16 cases. *Medicine (Baltimore).* 1962;**41:**35-91.
35. CALIN A, FRIES JF. An "experimental" epidemic of Reiter's syndrome revisited: follow-up evidence on genetic and environmental factors. *Ann Intern Med.* 1976;**84:**564-6.
36. GOOD AE. Reiter's disease: a review with special attention to cardiovascular and neurologic sequellae. *Semin Arthritis Rheum.* 1974;**3:**253-86.
37. FEINSTEIN AR, SPAGNUOLO M. The clinical patterns of acute rheumatic fever: a reappraisal. *Medicine (Baltimore).* 1962;**41:**279-305.
38. STEERE AC, BATSFORD WP, WEINBERG M. Lyme carditis: cardiac abnormalities of Lyme disease. *Ann Intern Med.* 1980;**93:**8-16.

Lyme Carditis: Cardiac Abnormalities of Lyme Disease

ALLEN C. STEERE, M.D.; WILLIAM P. BATSFORD, M.D.; MARC WEINBERG, M.D.; JONATHAN ALEXANDER, M.D.; HARVEY J. BERGER, M.D.; STEVEN WOLFSON, M.D.; and STEPHEN E. MALAWISTA, M.D.; New Haven, Connecticut

We studied 20 patients, mostly young adult men, with cardiac involvement of Lyme disease. The commonest abnormality (18 patients) was fluctuating degrees of atrioventricular block; eight of them developed complete heart block. Thirteen patients had evidence of more diffuse cardiac involvement: electrocardiographic changes compatible with acute myopericarditis (11 patients), radionuclide evidence of mild left ventricular dysfunction (five of 12 patients tested), or frank cardiomegaly (one patient). Heart involvement was usually preceded by erythema chronicum migrans and sometimes accompanied by meningoencephalitis, facial palsy, arthritis, elevated serum IgM levels, or cryoglobulins containing IgM. The duration of cardiac involvement was usually brief (3 days to 6 weeks). The clinical picture in these patients has similarities to acute rheumatic fever; but in Lyme disease, complete heart block may be commoner, myopericardial involvement tends to be milder, and valves seem not to be affected.

LYME DISEASE, thought to be transmitted by the newly described tick *Ixodes dammini* (1), usually begins in summer with a characteristic skin lesion, erythema chronicum migrans, which first appears at the site of the bite (2). Some patients, particularly those with the B-cell alloantigen DRw2 (3, 4), develop an abnormal immune response (5-8) associated days to months later with neurologic, cardiac, or joint involvement (2, 3, 9-11). Frank arthritis, often a later manifestation of the disease, usually occurs intermittently for several years but may become chronic in knees (3, 12). The endemic area for the disorder includes the northeastern coast of the United States, Wisconsin, California, and Oregon (1).

In this report, we describe 20 patients with cardiac abnormalities of Lyme disease.

► From the Departments of Internal Medicine, Diagnostic Radiology, and Epidemiology and Public Health, Yale University School of Medicine; New Haven, Connecticut.

Materials and Methods

Lyme disease was diagnosed in 19 of the 20 patients by the occurrence of erythema chronicum migrans. The lesion was defined by its gross appearance: a red macule or papule that expands to form a large annular lesion, usually with a bright red outer border and partial central clearing (2). Although one patient lacked this lesion, his remaining findings were like those of the other 19 patients.

Sixteen patients (one with onset of the illness in 1975, one in 1976, three in 1977, two in 1978, and nine in 1979) were studied prospectively through December 1979 according to the protocol outlined previously (2, 10). Patients with high-degree atrioventricular (AV) block were admitted to the coronary care unit for monitoring; those with first-degree block were usually treated as outpatients. Electrocardiograms and chest roentgenograms were obtained on all patients; M-mode echocardiograms and first-pass radionuclide angiocardiograms were done by previously described techniques (13-15), primarily on inpatients. At each visit, in addition to blood tests done on patients with all forms of the disease, sera from those with cardiac abnormalities were frozen at −70 °C and at the conclusion of the study, tested concomitantly for streptococcal antibodies: antistreptolysin 0, antihyaluronidase, and antideoxyribonuclease B. In five patients, acute and convalescent sera were tested for selected viruses, representative rickettsiae, *Chlamydia trachomatis*, and *Mycoplasma pneumoniae*, all by complement fixation, and in one patient, throat and rectal swab specimens were cultured for enteroviruses, as outlined before (2).

Four additional patients included in this report (one with onset of the illness in 1975 and three in 1979) were evaluated in other hospitals. All four had erythema chronicum migrans. Their histories and hospitals courses were reported to us by Dr. D. Rowett, Middlesex Hospital, Middletown, Connecticut; Drs. G. A. Jacoby and J. W. Harthorne, Massachusetts General Hospital, Boston, Massachusetts; and by Dr. J. C. Schlegelmilch, Mary Hitchcock Hospital, Hanover, New Hampshire. Follow-up information was obtained either from the referring physician or from the patient. The patient with onset in 1975 was originally reported elsewhere (Reference 16, Case Report 1) as having "non-specific carditis"; in retrospect, we are certain that she had Lyme disease, characterized by erythema chronicum migrans followed by complete heart block and then by intermittent arthritis.

Results

GENERAL CHARACTERISTICS

We studied 20 patients with cardiac abnormalities of Lyme disease. Their ages ranged from 6 to 58 years; 16 were male and four female (Table 1). Most were young adult men. In 18 patients, the illness began in summer with erythema chronicum migrans. One additional patient had the oneset with this lesion in December. Two patients remembered tick bites at the site of the lesion within 25 days of its onset. Associated signs and symptoms included malaise and fatigue, headache, stiff neck, fever, myalgias, sore throat, and regional or generalized lymphadenopathy, a picture sometimes suggestive of aseptic meningitis. These symptoms were usually intermittent and sometimes preceded the onset of erythema chronicum migrans. Soon after the initial skin lesion, 17 of the 19 patients developed many similar lesions on the trunk and extremities followed sometimes by evanescent lesions. Five patients also had a malar rash. The lesions usually disappeared completely within 3 to 4 weeks.

A median of 21 days (range, 4 to 83) after onset of erythema chronicum migrans, the 19 patients developed symptoms suggestive of heart disease or were found on examination to have cardiac involvement (Table 1). The commonest abnormality was fluctuating degrees of AV block, but 13 of the patients also had evidence for more diffuse cardiac involvement: electrocardiographic changes compatible with myopericarditis, radionuclide evidence of mild left ventricular dysfunction, or, in one instance, cardiomegaly. When heart disease was present, 15 patients still had skin lesions, and 10 were febrile (37.8 ° to 39 °C). Also, seven patients had meningoencephalitis (headache, stiff neck, cerebrospinal fluid pleocytosis, and abnormal electroencephalogram), with superimposed facial palsy in four (bilateral in two) and radiculoneuritis and myelitis in one each (Table 1). Thirteen patients had joint involvement: migratory polyarthritis in large and small joints in seven and oligoarticular arthritis more commonly in large joints in six. In three, the temporomandibular joint was affected. Only four patients had frank joint swelling. Migratory pains, sometimes lasting only hours in a given location, were common in tendons, bursae, muscle, and bone in addition to joints. Later in the illness, after cardiac abnormalities had resolved, five of the nine patients followed up for more than 1 year developed intermittent attacks of joint swelling and pain, most commonly in knees.

The remaining patient (Patient G), a 39-year-old man from the endemic area, had headache, stiff neck, and migratory joint pains in July without erythema chronicum migrans. Three weeks later, he developed complete heart block and had an elevated serum IgM level (330 mg/dL) and cryoglobulins containing IgM. Streptococcal antibody tests were normal and showed no change between acute and convalescent samples, throat culture grew only normal flora, and throat and rectal swab specimens did not show a cytopathic effect in tissue culture. On aspirin therapy, the heart block resolved within 1 week, but fatigue and intermittent arthralgias persisted through December 1979, the cutoff time for this study.

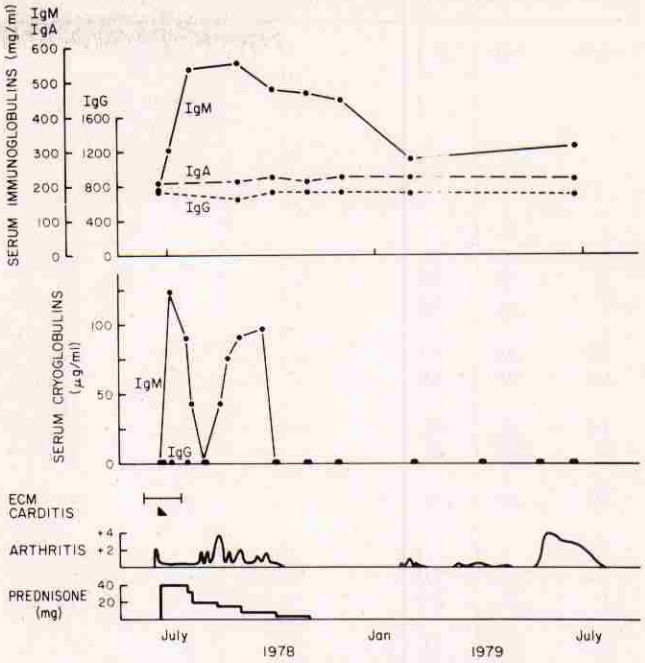

Figure 1. The clinical course of Patient A (described in the case report) is correlated with serum immunoglobulin and cryoglobulin levels. An elevated serum IgM level and cryoglobulins containing IgM developed when there was heart involvement. Months later, when arthritis became inactive, IgM levels returned toward normal and cryoglobulins disappeared. One year later, during recurrent attacks of arthritis, IgM was only slightly elevated and cryoglobulins were not present. ECM = erythema chronicum migrans.

The following case report illustrates cardiac involvement in this disorder.

CASE REPORT

Patient A: On 20 June 1978, a 31-year-old man from Lyme, Connecticut, noted an oval, bright red skin lesion, about 10 cm in diameter, over his umbilicus. He recalled no tick bites. During the next week, the skin lesion enlarged and similar ones appeared on the arms, legs, and back. On 1 July he began to have malaise and fatigue, headache, stiff neck, backache, myalgias (particularly in the right thigh), morning stiffness in the fingers of the right hand, and intermittent, migratory pain in the left knee and in several proximal interphalangeal joints. Five days later he experienced transient chest tightness and shortness of breath, as if drowning, and on the following day, blurred vision, confusion, hallucinations, and some loss of memory. Fatigue was incapacitating.

The patient was admitted to the hospital on 7 July. On examination, he had nine annular skin lesions, typical of erythema chronicum migrans, on the arms and trunk, and a malar rash. In addition, he had pain over flexor tendons of the right forearm, pain and swelling of the right fifth proximal interphalangeal joint, and mild tenderness on extreme neck flexion; Kernig's and Brudzinski's signs were negative. Blood pressure was 120/95 mg Hg, pulse 86 and regular, and temperature 37.3 °C. Findings on auscultation of the heart and lungs were normal. Hematocrit was 44%; leukocyte count, 10 500 cells/mm^3 with 78% polymorphonuclear leukocytes and 8% band forms; erythrocyte sedimentation rate, 20 mm/h; serum glutamic oxaloacetic transaminase, 45 KU/mL (normal <35); serum quantitative immunoglobulins, normal; and serum cryoglobulins, negative (Figure 1). Cerebrospinal fluid had 3 lymphocytes/mm^3 and total protein, 1 mg/dL; electroencephalogram was normal. Electrocardiogram showed first-degree AV block (PR interval = 0.40 s) with a narrow QRS complex.

Table 1. Clinical Findings in Patients with Cardiac Abnormalities of Lyme Disease*

Patient	Age	Sex	Other Systems			Heart		
			ECM†	Nervous System	Joints	Signs	Physical	Pulse
	yr							*beats/min*
A	30	M	+		+	Shortness of breath		30
B	36	M	+	+	+	Syncopy		40
C	26	M	+		+	Palpitations Syncopy		45
D§	20	F	+		+	Syncopy	Mitral insufficiency murmur	32
E§	19	M	+			Syncopy Chest pain		52
F§	22	M	+	+	+	Syncopy		60
G	39	M			+	Palpitations Chest pain		48
H§	40	M	+	+	+	Pericardial chest pain Shortness of breath	S_3 gallop Rales Pericardial rub	42
I	30	M	+		+	Dizziness	S_4 gallop	104
J	31	F	+		+	Palpitations Shortness of breath	S_3 gallop Hepatojugular reflex	72
K	58	M	+	+	+	Palpitations		~120
L	6	M	+					130
M	30	M	+		+			60
N	20	F	+	+	+			52
O	32	M	+		+			76
P	32	F	+		+	Palpitations		70
Q	35	M	+		+			80
R	23	M	+	+	+			96
S	23	M	+		+			76
T	19	M	+	+	+			84
Total			19	7	18			

* Abnormal findings are noted; normal or negative findings are blank except under pulse, PR interval, and radionuclide scan where all available values are listed.
† Erythema chronicum migrans.
‡ Left ventricular ejection fraction; normal value ≥55%.
§ Personal communication. Patient D (16), D Rowett; Patient E, JW Harthorne; Patient F, GA Jacoby, and Patient H; JC Schlegelmilch.
‖Patient K also had atrial fibrillation.

During the next 3 hours in the coronary care unit, he had rapidly changing periods of first-, second-(Wenckebach), and third-degree (complete) AV block with an escape rhythm of 30. High degrees of AV block were accompanied by escape beats that sometimes had a wide QRS complex (0.12 s). Oral prednisone, 20 mg twice a day, was begun. Within several hours, his headache, stiff neck, and joint pain improved, and the skin lesions began to fade. He continued to have periods of first- and second-degree AV block for the following 24 hours, but had no more episodes of complete heart block. After 48 hours, he had only first-degree block (PR interval = 0.30 s) with a normal QRS complex. A first-pass radionuclide angiocardiogram showed a mildly reduced left ventricular ejection fraction of 51% (normal: ≥55%), but chest roentgenogram was normal. Results of streptococcal antibody tests were normal (antistreptolysin O, 1:64; antihyaluronidase, 1:128; and deoxyribonuclease B, 1:160); throat culture grew only normal flora. Five days later at discharge, cryoglobulins containing IgM were present (total protein, 324 μg/mL; IgM, 126 μg/mL), serum IgM level was elevated (305 mg/mL), sedimentation rate was lower (15 mm/h), and streptococcal serologic findings were unchanged. The PR interval gradually shortened to normal within the next 2 weeks. Prednisone was tapered by about 5 mg/week.

By 15 August, 5 weeks after prednisone was started, the patient had only mild, intermittent musculoskeletal pain and mild fatigue; cryoglobulins disappeared, but the serum IgM level remained elevated. When the prednisone dose was reduced to 20 mg/d, he again experienced headache, stiff neck, and migratory joint pains. Cryoglobulins reappeared (Figure 1). The schedule of prednisone reduction was slowed, and his symptoms gradually improved. On 13 September, prednisone was tapered to 10 mg/d and indomethacin, 25 mg three times a day, was begun for musculoskeletal pain. A repeat radionuclide angiocardiogram showed a normal left ventricular ejection fraction of 69%. Cryoglobulins disappeared by October, prednisone was stopped by November, and the serum IgM level was near normal in February (Figure 1). During the next 6 months, he had intermittent attacks of arthritis, but findings of electrocardiograms and streptococcal serologic studies, done at each follow-up visit, were normal.

SIGNS AND SYMPTOMS OF CARDIAC INVOLVEMENT

All 10 patients with high degree AV block developed symptoms suggestive of cardiac involvement (Table 1). They had syncopy or dizziness, shortness of breath, as if drowning or choking, substernal chest pain, exacerbated by deep inspiration and lying down (Patient H only), or palpitations. In contrast, of the eight patients with no more than first-degree block, only two had palpitations.

On examination, the commonest clue to cardiac involvement (10 patients) was tachycardia or bradycardia (Table 1). Two patients with high-degree AV block had loud S_3 gallops; one of them had mild hepatojugular re-

Table 1. (Continued)

Electrocardiograph							Radiograph			Patient
Atrioventricular Block			Interval		ST Segment Depression	T Wave Inversion	Radionuclide Scan (LVEF)‡		Chest Roentgen-ogram	
First-Degree	Wenckebach	Complete	PR	QRS			Active	Remission		
			s				%			
+	+	+	0.40	0.12			51	69		A
+	+	+	0.33			+	72			B
+	+	+	0.40							C
+		+	0.42			+				D
+		+				+				E
+	+	+							Cardiomegaly	F
+	+	+	0.30	0.15		+				G
+	+	+				+				H
+	+		0.30				53	61		I
+	+		0.32			+	69			J
+‖			0.24		+	+	47	56		K
+			0.24							L
+			0.28	0.12			62			M
+			0.24				74			N
+			0.24							O
+			0.30				70			P
+			0.23			+				Q
+			0.22			+				R
			0.18			+				S
			0.18		+		52			T
18	8	8			2	10				Total

flux (Patient J), and the other had a pericardial friction rub and a few bibasilar rales (Patient H).

ELECTROCARDIOGRAPHIC ABNORMALITIES

Eighteen of the 20 patients had AV block; 10 of them had high-degree block (sometimes complete in eight, only Wenckebach in two) (Table 1). The degree of AV block often fluctuated rapidly; in all patients with complete block, first degree and Wenckebach-type second degree block were also seen. Some patients went from first-degree to complete block and back within minutes. Therefore, in all patients, AV block appeared to be proximal to the bundle of His, a finding documented in two patients (Patients B and G) by His bundle studies obtained during periods of high-degree block (Figure 2). While in complete block, the eight patients had escape rates between 30 and 60 (one of them, Patient D, had asystole for 30 seconds when first seen); in first degree block, their PR intervals ranged from 0.30 to 0.42 seconds. In contrast, the eight patients who remained in first-degree block had PR intervals that ranged from 0.22 to 0.30 seconds. No patient had bundle branch block.

Thirteen of the 20 patients had electrocardiographic evidence of more diffuse cardiac involvement (Table 1). Ten patients, including one who did not have AV block (Patient S), had diffuse T-wave flattening or inversions, most commonly in the inferior and lateral leads. One of them (Patient K) and an additional patient without AV block (Patient T) had diffuse ST segment depression in the anterolateral leads. (The latter patient's echocardiogram indicated the presence of a small pericardial effusion, and his radionuclide angiocardiogram showed a reduced left ventricular ejection fraction [52%].) Three patients, including two of the above, had intraventricular conduction defects (QRS interval = 0.12 s) and ventricular premature contractions. With remission, electrocardiograms in all patients returned to normal.

In addition to ST-T wave changes, a 58-year-old man (Patient K), the oldest in this series, presented in atrial fibrillation with a ventricular response of about 120. He had no previous history of heart disease, exercise intolerance, or hypertension and was not taking digitalis glycosides. After resolution of the fibrillation, he developed first-degree AV block (PR interval = 0.24 s) for 1 week. During remission, electrocardiograms and an exercise thallium-201 perfusion scan were normal.

RADIOGRAPHIC FINDINGS

When heart involvement was active, four of 12 patients had mildly reduced left ventricular ejection fractions (47% to 53%, normal $\geq$55%) ascertained by radionuclide angiocardiogram (Table 1). One of them, Patient T, also had a small pericardial effusion on echocardiogram. The three ejection fractions, repeated in remission, had

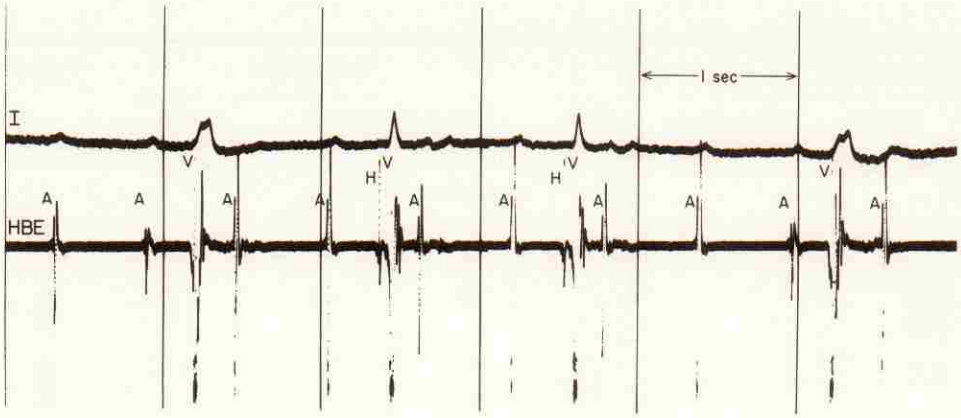

Figure 2. An electrocardiographic tracing of lead 1 *(I)* and a simultaneous His bundle electrogram *(HBE)* are shown during a period of high-degree atrioventricular (AV) nodal block (Patient B). Ventricular beats 2 and 3 are conducted; the atrio *(A)*-His *(H)* interval is markedly prolonged (300 ms), but the His bundle deflection is followed within a normal interval (50 ms) by a narrow QRS complex *(V)*. One and 4 are ventricular escape beats with a wide QRS. The p waves are not followed by His bundle deflections because of AV nodal block.

increased 8% to 18% to values in the normal range. All patients tested had normal valvular structures, chamber dimensions, and wall thickness on echocardiogram and normal regional wall motion on radionuclide studies.

Only one patient (Patient F), a 22-year-old man who did heavy physical labor until hospital admission, had an abnormal chest roentgenogram; it showed cardiomegaly and pulmonary venous hypertension. He did not have radionuclide or echocardiographic studies. Five days after treatment with prednisone, the chest roentgenogram was normal.

LABORATORY FINDINGS

The commonest laboratory abnormalities were an elevated erythrocyte sedimentation rate (18 patients), an elevated serum IgM level (14 patients), and cryoglobulins (13 patients) containing IgM and sometimes IgG (Table 2). However, immunoglobulin and cryoglobulin abnormalities sometimes developed several days to weeks after the onset of heart disease and disappeared months after remission of carditis when involvement in other systems became inactive (*see* Case Report). Six patients had mild elevations of serum glutamic oxaloacetic transaminase, eight had elevated leukocyte counts with shifts to the left in the differential count, and four were anemic.

During active myocarditis, one patient (Patient F), who had erythema chronicum migrans in summer followed by meningoencephalitis, AV block, and then arthritis, had an elevated antistreptolysin O titer (1:833). Three months later the titer, measured in a different laboratory, was 1:256. The remaining 19 patients had normal findings of streptococcal serologic studies that showed no change between acute and convalescent samples. Five patients, including Patient G who did not have erythema chronicum migrans, had sera tested for antibodies against adenoviruses, cytomegalovirus, herpes simplex, influenza types A and B, lymphocytic choriomeningitis, measles, mumps, rubella, and varicella viruses; rickettsiae (*Rickettsia rickettsii, R. akari, R. mooseri,* and *Coxiella burnetii); Mycoplasma pneumoniae;* and *Chlamydia trachomatis.* Titers were either negative or showed no change between acute and convalescent sera.

TREATMENT AND DURATION OF HEART INVOLVEMENT

Nine patients, seven with high-degree and two with first-degree AV block, were treated with prednisone, 40 to 60 mg/d in divided doses (Figure 3). (The latter two patients were given this medication for treatment of meningoencephalitis rather than heart disease.) Within 24 to 48 hours, the degree of block decreased in all nine; cardiac abnormalities usually resolved completely within 1 to 2 weeks. Prednisone was generally tapered 5 to 10 mg/week. Because of recurrent nervous system or joint symptoms, 2 to 4 months of therapy were usually needed before the medication could be stopped. The course of Patient I was different from the others; he continued to have occasional episodes of first-degree and Wenckebach block for 5 months. Prednisone was stopped after the first 3 months.

Nine additional patients were treated with aspirin, generally 3.6 g/d in divided doses. The three patients with complete heart block had resolution within 1 week, those with first-degree block, in 1 to 6 weeks. In one patient who refused aspirin, first-degree block lasted 4 weeks. In the two patients who did not have AV block, ST-T wave changes resolved in a few days both in one patient who took aspirin and in another who did not. Joint symptoms did not respond dramatically to aspirin.

Six of the eight patients with complete heart block had temporary transvenous pacemakers inserted. In all instances, the pacemakers were removed within 1 week.

Eight of 20 patients received penicillin for erythema chronicum migrans a median of 18 days (range 1 to 31) after onset of the lesion; six of them already had cardiac involvement. The other two received it 8 and 16 days after onset of the skin lesion and 28 and 67 days, respectively, before onset of cardiac involvement. In the eight patients who received penicillin, the median duration of cardiac involvement was 0.75 weeks (range, 0.3 to 24); in the 12 patient who did not, the median duration was 1 week (range, 0.5 to 6) (P= not significant).

Discussion

CARDIAC ABNORMALITIES

We studied 20 patients with cardiac abnormalities of Lyme disease, an unusual complication found in 8% of patients in one epidemiologic study of this illness (11). The commonest abnormality was varying degrees of AV block, and eight of the patients developed complete heart block often accompanied by syncopy. By standard electrocardiographic criteria for AV nodal block (17)—fluc-

tuating first-degree, Wenckebach-type second-degree, and complete block, all with narrow QRS complexes—the block appeared to be proximal to the bundle of His in all patients (confirmed by His bundle studies in two patients). However, of the 10 patients with high-degree AV block, two had widening of escape QRS complexes suggesting a subjunctional escape focus.

Thirteen of the 20 patients had evidence of more diffuse cardiac involvement, most commonly, electrocardiographic changes compatible with myopericarditis. In addition to these changes, Patient H had a pericardial friction rub, and Patient T had a small pericardial effusion on echocardiogram. Patient K, the oldest in the series, presented in atrial fibrillation followed by first-degree block. Although we cannot rule out pre-existing heart disease, we were unable to detect it by study of history, subsequent cardiograms, or an exercise thallium-201 perfusion scan, done to detect occult coronary artery disease (18). Thus, we believe that his cardiac abnormalities were probably due to Lyme disease. Four of 12 patients tested had mild, clinically inapparent, left ventricular dysfunction shown by radionuclide angiocardiogram. The three ejection fractions repeated in remission had returned to normal. Only one patient (Patient F) had frank cardiomegaly and pulmonary venous hypertension. He may have exacerbated his condition by doing heavy physical labor until the day of hospitalization. We do not yet know whether cardiac involvement in this disorder may lead to later sequelae. Currently, after 6 months to 4 years of follow-up, all 20 patients have normal cardiac findings on examination.

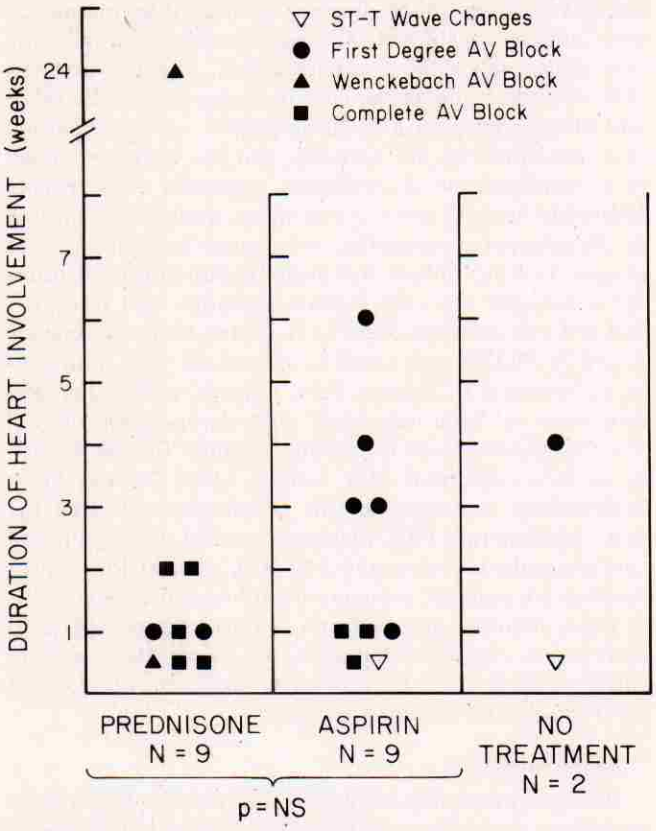

Figure 3. The treatment and duration of cardiac involvement are shown in 20 patients. Nine patients treated with prednisone, most of whom had high-degree atrioventricular *(AV)* block, had improvement in the degree of block within 24 to 48 hours and complete resolution of cardiac abnormalities within 1 to 2 weeks. However, one of them continued to have intermittent Wenckebach or first-degree block for 5 months. Nine patients treated with aspirin, most of whom had first-degree block, had resolution within 1 to 6 weeks ($P = [NS]$). Two patients with mild cardiac involvement elected not to take aspirin; they had remissions within 4 weeks.

Table 2. Laboratory Findings in 20 Patients with Cardiac Abnormalities of Lyme Disease

Test*	Normal Range	Patients	
		Median	Range
Hematocrit, %	37–47	40	31–48
Leukocytes, *cells/mm³* × 10^{-3}	4.3–10	9.1	6.6–18
PMNs, %	25–62	68	39–83
Band forms, %	0–21	4	0–13
ESR, *mm/h*	<20	47	3–74
SGOT, *KU/mL*	<35	34	10–105
Serum cryoglobulins, *μg/mL**			
Total protein	<80	164	8–707
IgM	0	22	0–126
IgG	0	0	0–60
IgA	0	0	0–18
Serum immunoglobulins, *mg/dL*			
IgM	20–250	376	79–625
IgG	600–1500	1055	520–2100
IgA	60–400	210	90–656
Streptococcal enzymes‡			
Antistreptolysin O	<160	32	0–833
Antihyaluronidase	<256	64	0–256
Antideoxyribonuclease B	<240	120	0–240

* PMN = polymorphonuclear neutrophilic leukocytes; ESR = erythrocyte sedimentation rate; SGOT = serum glutamic oxaloacetic transaminase.
† Serum cryoglobulins and immunoglobulins were not measured in Patient D.
‡ Antihyaluronidase and antideoxyribonuclease B tests were not done in Patients D, E, and H.

DIAGNOSTIC FINDINGS

Lyme disease was recognized in the 20 patients primarily by extracardiac findings. About 3 weeks before cardiac involvement, 19 of them had the onset of erythema chronicum migrans, the best clinical marker for the illness (2), and most still had multiple skin lesions when heart disease was present. Some patients also had migratory polyarthritis, oligoarticular arthritis, meningoencephalitis, or facial palsy, findings typical of other patients with nervous system or joint abnormalities of Lyme disease. All 20 patients came from the known endemic area (1), and except for one, had onset of the illness in summer. In this small series, adult men were most commonly affected, as is apparently the case with other severe manifestations of Lyme disease—meningoencephalitis (10) and chronic arthritis (3). In contrast, there seems to be no age or sex predilection for the milder forms of the disorder (2, 9-11). The commonest laboratory findings in the current patients were an elevated erythrocyte sedimentation rate, an elevated serum IgM level, cryoglobulins containing IgM, and negative serologic findings for other diseases, findings also typical of other patients with erythema chronicum migrans who later develop nervous system or joint involvement (2, 7, 10). Patient G lacked a history of erythema chronicum migrans, but his age, sex,

geographic location, clinical course, immune abnormalities, normal serologic findings, and negative culture results were like those of the other 19 patients reported here. Although we cannot prove that he had Lyme disease, his illness seems most compatible with that diagnosis.

DIFFERENTIAL DIAGNOSIS

Acute Rheumatic Fever: Jones' (19) major clinical criteria for acute rheumatic fever include carditis, arthritis, chorea, erythema marginatum, and subcutaneous nodules. Except for erythema marginatum, which superficially resembles erythema chronicum migrans, we have seen all of those manifestations, with certain differences, in patients with Lyme disease.

In acute rheumatic fever, carditis affects primarily children between ages 5 and 15 and is frequently asymptomatic (20, 21). Valvular involvement is the commonest cardiac manifestation; about 8% develop congestive heart failure and 6%, pericarditis (22). These findings correlate with subsequent heart damage (23). Approximately 25% to 50% of patients with acute rheumatic fever had prolonged PR intervals (21, 22, 24) (one of Jones' minor clinical criteria), but complete heart block is unusual (25), and these abnormalities do not correlate with significant heart disease (23, 26). In contrast, in the current patients, adult men were most frequently affected, complete heart block was common, myopericardial involvement tended to be mild, and valves seemed not to be affected (the only possible exception is Patient D, who was thought to have a transient mitral regurgitation murmur [16]).

Arthritis may be similar in both diseases. Patterns of joint involvement include mono-oligoarticular pain and swelling, particularly in large joints in the lower extremities, and migratory polyarthritis (2, 27, 28); joint fluid leukocyte counts range from 2000 to 100 000 cells/mm^3 and consist predominantly of polymorphonuclear leukocytes (2, 27, 29). However, in Lyme disease, the temporomandibular joint is affected more often, attacks commonly recur for several years, and the response to aspirin is rarely dramatic (2). Chorea, the characteristic neurologic manifestation of acute rheumatic fever, has a propensity for young girls (21) and often occurs alone (20, 21). In Lyme disease, three children with meningoencephalitis also had chorea (10), but we have not seen it as an isolated finding. However, an important distinction between the two diseases is that other neurologic involvement—headache, stiff neck, and frank meningoencephalitis—may accompany cardiac involvement in Lyme disease. Erythema marginatum and subcutaneous nodules occur in less than 5% of patients with acute rheumatic fever (20) and therefore are usually not helpful in diagnosis. Five patients with Lyme arthritis have had subcutaneous nodules on extensor tendons, but none of the current patients had this finding. However, 15 of 20 patients with cardiac involvement had multiple secondary lesions of erythema chronicum migrans sometimes followed by evanescent lesions, a picture that might be confused with erythema marginatum. But the former lesions are generally larger, fewer in number, more widely scattered, and slower moving.

Because several other diseases may produce a similar clinical picture, the revised Jones criteria require evidence of preceding streptococcal infection to make the diagnosis of acute rheumatic fever (30). However, 20% of asymptomatic persons may be colonized with group A streptococci in the throat (31), and as many as 20% of normal children may have an elevated antistreptolysin 0 titer (32) (titers commonly remain elevated for 2 to 12 months after infection [33]). Thus, Ward (34) recently suggested another revision of the Jones criteria: that evidence of preceding streptococcal infection be supported by exclusion of other possible causes. Patient F demonstrates this problem. When heart disease was active, he had an elevated antistreptolysin 0 titer (1:833); 3 months later, it was 1:256. However, he was a 22-year-old man from Cape Cod who had the onset of erythema chronicum migrans in July followed by meningoencephalitis, complete AV block, and then arthritis. Thus, in spite of the streptococcal serologies, his clinical findings favor the diagnosis of Lyme disease rather than acute rheumatic fever.

Further Differential Diagnosis: In addition to acute rheumatic fever, other illnesses with cardiac manifestations may be considered. *Yersinia enterocolitica* infection may cause valvulitis, myopericarditis, and polyarthritis (35). However, unlike the case in Lyme disease, diarrhea and abdominal pain are characteristic, cardiac conduction abnormalities are unusual, and the only associated skin manifestation is erythema nodosum (36). Rocky Mountain spotted fever, a rickettsial disease transmitted by *Dermacentor variabilis,* may cause myocarditis and congestive heart failure, but prolongation of the PR interval is unusual, the rash is maculopapular and purpuric, and arthritis does not occur (37). Of the viruses coxsackie A and B, ECHO type 6 and 8, adenovirus type 3, influenza A, hepatitis B, Epstein-Barr, mumps, polio, and varicella have all been associated with myopericarditis (38, 39). Coxsackieviruses B probably account for the majority of these infections (40). Unlike Lyme disease, heart involvement in coxsackievirus B infections is often the first manifestation (40), pleuropericardial chest pain and cardiomegaly are common (40, 41), conduction abnormalities are unusual, recovery from heart disease generally takes months, and arthritis is not described (41). In addition to clinical differences, the above diseases were ruled out in five of our patients by serologic tests (except for *Yersinia* and the enteroviruses).

PATHOGENESIS

We have previously suggested that circulating immune complexes may play a pathogenetic role in Lyme disease (5-8), and 3 patients with carditis who were tested did have abnormal Clq binding activity in serum (8). On the other hand, the presence of cryoglobulins does not correlate well with cardiac involvement (*see* Case Report). (Cryoglobulins containing IgM are less sensitive indicators of the presence of immune complexes than is Clq binding activity [8], but when they accompany erythema

chronicum migrans, they predict subsequent nerve, heart, or joint involvement [7].) In experimental serum sickness, a known immune-complex disorder, C3, is often low (42); in both Lyme disease and acute rheumatic fever, C3 usually behaves as an acute-phase reactant (27, 29). In acute rheumatic fever, currently favored hypotheses are that heart damage results not from circulating immune complexes, which may be present (43, 44), but rather from antibodies against group A streptococci that cross-react with myocardial fibers (46, 47) or from sensitized lymphocytes that attack the fibers (48, 49). So far in Lyme disease, there is no basis on which to choose among these possible mechanisms.

TREATMENT

Although cardiac sequelae have not been described in Europe, erythema chronicum migrans is well known and is said to respond promptly to therapy with penicillin or tetracycline (50) (see Addendum). For this reason, eight of the 20 current patients received antibiotic therapy. However, because erythema chronicum migrans is often recognized as unique only as the lesion expands during the second or third week, all but two patients had both skin and heart involvement when we first saw them. In those 2 patients, given penicillin within 2 weeks after onset of erythema chronicum migrans, heart involvement still developed later. Regardless of antibiotic therapy, the duration of heart involvement was usually brief.

We are uncertain of the advisability of prednisone for heart involvement. Because the first patient who received it got better, most of our patients with high-degree AV block were given that medication. All had improvement in the degree of block within 24 to 48 hours, and all except one had complete resolution within 1 to 2 weeks. Although resolution of first-degree block often took longer on aspirin (1 to 6 weeks), three patients with complete heart block treated with aspirin had resolution within 1 week. The major disadvantage of prednisone was that 2 to 4 months of therapy were usually needed because of recurrent nervous system or joint involvement before the medication could be stopped.

RECOMMENDATIONS

Patients who have high-degree AV block or first-degree block with a PR interval longer than 0.30 seconds should be hospitalized because they seem at marked risk to develop complete heart block (one such patient, a 20-year-old girl, had asystole for 30 seconds when first seen). We told patients with slightly prolonged PR intervals to restrict their activity, but followed them as outpatients. Currently, even in patients with complete heart block, it may be preferable to begin therapy with a temporary pacemaker and aspirin, generally 3.6 gd. However, we would still treat with prednisone, 40 to 60 mg/d in divided doses, if the patient also has meningoencephalitis (seven of 20 current patients), complete AV block for longer than 1 week, or deterioration of cardiac status with cardiomegaly. Prednisone can usually be tapered 5 to 10 mg/week. If joint symptoms become greater at lower doses, we generally begin a nonsteroidal anti-inflammatory agent as well and try to continue tapering prednisone (*see* Addendum).

ACKNOWLEDGMENTS: the authors thank Drs. George A. Jacoby, John W. Harthorne, Dale Rowett, and John C. Schlegelmilch who generously contributed information about patients not seen at Yale. The authors also thank the physicians who referred patients; Drs. Nicholas H. Bartenhagen, Phyllis Spieler, Alan Spagnola, Theodore I. Tyberg, James H. Newman, and Gloria E. Singleton for help with patient care; Dr. Francis Steele for viral, rickettsial, mycoplasma, and chlamydial serologies; Ms. Stella Cretella for expert laboratory assistance; Ms. Elise DeSanna for preparation of the manuscript, and Drs. Alvan R. Feinstein, John A. Hardin, and Lawrence S. Cohen for review of it.

Grant support: in part by U.S. Public Heath Service Grants AM-20358, AM-10493, AM-07107, AM-5639, RR-05443, RR-00125, HL21690; the Arthritis Foundation and its Connecticut Chapter; and the Kroc Foundation, Santa Ynez, California.

▶ Requests for reprints should be addressed to Allen C. Steere, M.D.; Department of Internal Medicine, Yale University School of Medicine, 333 Cedar Street; New Haven, CT 06510.

Addendum

On the basis of work published elsewhere in this issue (51), we treat erythema chronicum migrans with oral penicillin G, 250 000 U four times a day, or (except children) tetracycline, 250 mg four times a day, each for 7 to 10 days. However, we have no evidence that these medications are best, that such dosage or duration of therapy is optimal, or that carditis is affected.

References

1. STEERE AC, MALAWISTA SE. Cases of Lyme disease in the United States: locations correlated with distribution of *Ixodes dammini*. *Ann Intern Med.* 1970;**91:**730-3.
2. STEERE AC, MALAWISTA SE, HARDIN JA, RUDDY S, ASKENASE PW, ANDIMAN WA. Erythema chronicum migrans and Lyme arthritis: the enlarging clinical spectrum. *Ann Intern Med.* 1977;**86:**685-98.
3. STEERE AC, GIBOFSKY A, PATARROYO ME, WINCHESTER RJ, HARDIN JA, MALAWISTA SE. Chronic Lyme arthritis: clinical and immunogenetic differentiation from rheumatoid arthritis. *Ann Intern Med.* 1979;**90:**896-901.
4. STEERE AC, GIBOFSKY A, HARDIN JA, WINCHESTER RJ, MALAWISTA SE. Lyme arthritis: immunologic and immunogenetic markers. *Arthritis Rheum.* 1979;**22:**662. Abstract.
5. STEERE AC, HARDIN JA, MALAWISTA SE. Erythema chronicum migrans and Lyme arthritis: cryoimmunoglobulins and clinical activity of skin and joints. *Science.* 1977;**196:**1121-2.
6. HARDIN JA, WALKER LC, STEERE AC, et al. Circulating immune complexes in Lyme arthritis: detection by the ^{125}I-Clq binding, Clq solid phase, and Raji cell assays. *J Clin Invest.* 1979;**63:**468-77.
7. STEERE AC, HARDIN JA, RUDDY S, MUMMAW JG, MALAWISTA SE. Lyme arthritis: correlation of serum and cryoglobulin IgM with activity and serum IgG with remission. *Arthritis Rheum.* 1979;**22:**471-83.
8. HARDIN JA, STEERE AC, MALAWISTA SE. Immune complexes and the evolution of Lyme arthritis: dissemination and localization of abnormal Clq binding activity. *N Engl J Med.* 1979;**301:**1358-63.
9. STEERE AC, MALAWISTA SE, SNYDMAN DR, et al. Lyme arthritis: an epidemic of oligoarticular arthritis in children and adults in three Connecticut communities. *Arthritis Rheum.* 1977;**20:**7-17.
10. REIK L, STEERE AC, BARTENHAGEN NH, SHOPE RE, MALAWISTA SE. Neurologic abnormalities of Lyme disease. *Medicine (Baltimore).* 1979;**58:**281-94.
11. STEERE AC, BRODERICK TF, MALAWISTA SE. Erythema chronicum migrans and Lyme arthritis: epidemiologic evidence for a tick vector. *Am J Epidemiol.* 1978;**108:**312-21.
12. STEERE AC, BRINCKERHOFF CE, MILLER DJ, DRINKER H, HARRIS ED JR, MALAWISTA SE. Elevated levels of collagenase and prostaglandin E_2 from synovium associated with erosion of cartilage and bone in a patient with chronic Lyme arthritis. *Arthritis Rheum.* 1980;**23:** 591-9.
13. MARSHALL RC, BERGER HJ, COSTIN JC, et al. Assessment of cardiac performance with quantitative radionuclide angiocardiography: sequential left ventricular ejection fraction, normalized left ventricular ejection rate, and regional wall motion. *Circulation.* 1977;**56:**820-9.
14. BERGER H, MATTHAY R, PYTLIK L, GOTTSCHALK A, ZARET B. First-pass radionuclide assessment of right and left ventricular performance in patients with cardiac and pulmonary disease. *Semin Nucl Med.* 1979;**9:**275-95.
15. TEICHHOLZ L, KREULEN T, HERONAN A, HERMAN M, GORLIN R. Problems in echocardiographic volume determinations: echocardio-

graphic-angiographic correlations in the presence or absence of asynergy. *Am J Cardiol.* 1976;**37:**7-11.
16. KIRMSER R, UMBACH R, ROWETT D, ROSS A. Complete heart block due to acute nonspecific carditis. *Chest.* 1977;**71:**682-4.
17. JAMES TN. Cardiac arrhythmias and conduction disturbances. In: HURST JW, LOGUE RB, SCHLANT RC, WENGER NK, eds. *The Heart.* 4th ed. New York: McGraw-Hill; 1978:675.
18. RITCHIE J, ZARET B, STRAUSS W, et al. Myocardial imaging with thallium-201 at rest and exercise: a multicenter study in patients with angina pectoris or acute myocardial infarction. *Am J Cardiol.* 1978;**42:**345-50.
19. JONES TD. Diagnosis of rheumatic fever. *JAMA.* 1944;**126:**481-4.
20. FEINSTEIN AR, SPAGNUOLO M. The clinical patterns of acute rheumatic fever: a reappraisal. *Medicine (Baltimore).* 1962;**41:**279-305.
21. TARANTA A. Rheumatic fever. In: MCCARTY DJ JR, ed. *Arthrutis and Allied Conditions.* 9th ed. Philadelphia: Lea & Febiger; 1979:825-70.
22. MASSELL BF, FYLER DC, ROY SB. The clinical picture of rheumatic fever. *Am J Cardiol.* 1958;**1:**436-49.
23. FEINSTEIN AR, DIMASSA R. Prognostic significance of valvular involvement in acute rheumatic fever. *N Engl J Med.* 1959;**260:**1001-7.
24. MIROWSKI M, ROSENSTEIN BJ, MARKOWITZ M. A comparison of atrio-ventricular conduction in normal children and in patients with rheumatic fever, glomerulonephritis, and acute febrile illness. *Pediatrics.* 1964;**33:**334-40.
25. FRIEDBURG CK. Rheumatic fever. In: *Diseases of the Heart.* 3rd ed Philadelphia: W. B. Saunders Co.; 1966:1334.
26. CRISTAL N, STERN J, GUERON M. Artrioventricular dissociation in acute rheumatic fever. *Br Heart J.* 1971;**33:**12-5.
27. BARNERT AL, TERRY EE, PERSELLIN RH. Acute rheumatic fever in adults. *Jama.* 1975;**232:**925-8.
28. MCDANALD EC, WEISMAN MH. Articular manifestations of rheumatic fever in adults. *Ann Intern Med.* 1978:**89:**917-20.
29. SVARTMAN M, POTTER EV, POON-KING T, EARLE D. Immunoglobulins and complement components in synovial fluid of patients with acute rheumatic fever. *J Clin Invest.* 1975;**56:**111-7.
30. STOLLERMAN GH, MARKOWITZ M, TARANTA A, WANNAMAKER LW, WHITTEMORE R. Jones' criteria (revised) for guidance in the diagnosis of rheumatic fever. *Circulation.* 1965;**32:**664-8.
31. BRUMFITT W, O'GRADY F, SLATER JDH. Benign streptococcal sore throat. *Lancet* 1959;**2:**419-23.
32. RANTZ LA, RANDALL E, RANTZ HH. Antistreptolysin 'O:' A study of this antibody in health and in hemolytic streptococcus respiratory disease in man. *Am J Med.* 1948;**5:**3-23.
33. STOLLERMAN GH, LEWIS AJ, SCHULTZ I, TARANTA A. Relationship of immune response to group A streptococci to the course of acute, chronic and recurrent rheumatic fever. *Am J Med.* 1956:**20:**163-9.
34. WARD C. Observation on the diagnosis of isolated rheumatic carditis. *Am Heart J.* 1976;**91:**545-50.
35. LAITINEN O, LEIRISALO M, ALLANDER E. Rheumatic fever and Yersinia arthritis: criteria and diagnostic problems in a changing disease pattern. *Scand J Rheumatol.* 1975;**4:**145-57.
36. JOHNSON JE. Yersinia (Pasteurella) infections including plague. IN: THORN GW, ADAMS RD, BRAUNWALD E, et al. eds. *Harrison's Principles of Internal Medicine.* 8th ed. New York: MCGRAW-HILL; 1977:864.
37. WOODWARD TE, MCCRUMB FR JR, CAREY TN, TOGO Y. Viral and rickettsial causes of cardiac disease, including the Coxsackie virus etiology of pericarditis and myocarditis. *Ann Intern Med.* 1960;**53:**1130-50.
38. FRIEDBERG CK. The heart in infections. *See* Reference 25, p. 1464.
39. PANKEY GA. Effect of viruses on the cardiovascular system. *Am J Med Sci.* 1965;**250:**103-14.
40. HIRSCHMAN SZ, HAMMER GS. Coxsackie virus myopericarditis: a microbiological and clinical review. *Am J Cardiol.* 1974;**34:**224-32.
41. SMITH WG. Coxsackie B myopericarditis in adults. *Am Heart J.* 1970;**80:**34-46.
42. COCHRANE CG, DIXON FJ. Immune complex injury. In: SAMTER M, TALMAGE DW, eds. *Immunological Diseases.* Boston: Little, Brown and Co.; 1965:210-29.
43. VAN DE RIJN I, FILLIT H, BRANDEIS WE, et al. Serial studies on circulating immune complexes in post-streptococcal sequelae. *Clin Exp Immunol.* 1978;**34:**318-25.
44. YOSHINOYA S, POPE RM. Detection of immune complexes in acute rheumatic fever and their relationship to HLA-B5. *J Clin Invest.* 1980;**65:**136-45.
45. RAMMELKAMP CH JR, STOLZER BL. The latent period before the onset of acute rheumatic fever. *Yale J Biol Med.* 1961/2;**34:**386-98.
46. KAPLAN MH. Immunologic studies of heart tissue: 1. Production in rabbits of antibodies reactive with an autologous myocardial antigen following immunization wtih heterologous heart tissue. *J Immunol.* 1958;**80:**254-67.
47. HESS EV, FINK CW, TARANTA A, ZIFF M. Heart muscle antibodies in rheumatic fever and other diseases. *J Clin Invest.* 1964;**43:**886-93.
48. TARANTA A, CUPPARI G, QUAGLIATA F. Dissociation of hemolytic and lymphocyte-transforming activities of streptolysin S preparations. *J Exp Med.* 1969;**129:**605-22.
49. YANG LC, SOPREY PR, WITTNER MK, FOX EN: Streptococcal-induced cell-mediated-immune destruction of cardiac myofibers in vitro. *J Exp Med.* 1977; **146:**344-60.
50. HOLLSTRÖM E. Penicillin treatment or erythema chronicum migrans Afzelius. *Acta Derm Venereol (Stockh.)* 1958;**38:**285-9.
51. STEERE AC, MALAWISTA SE, NEWMAN JH, SPIELER PN, BARTENHAGEN NH. Antibiotic therapy in Lyme disease. *Ann Intern Med.* 1980; **93:**1-8.