



Preliminary evaluation of the anti-inflammatory and anti-hepatotoxic activities of 'Parsley' *Petroselinum crispum* in rats

T. A. Al-Howiriny¹, M. O. Al-Sohaibani², K. H. El-Tahir¹, S. Rafatullah^{1*}

1. Medicinal, Aromatic and Poisonous Plants Research Center (MAPPRC), College of Pharmacy, King Saud University, P.O. Box 2457, Riyadh 11451, Saudi Arabia.

2. Department of Pathology, College of Medicine, King Khalid University Hospital, King Saud University, P.O. Box 2925 Riyadh 11461, Saudi Arabia

Received 17 July 2002 ; Accepted 22 August 2002

Abstract

Objective: To study the anti-inflammatory and hepatoprotective properties of an ethanolic extract of Parsley '*Petroselinum crispum*' leaves. **Materials and methods:** An ethanolic extract of Parsley was subjected for evaluation of anti-inflammatory and anti-hepatotoxic activities against inflammation induced by carrageenan and cotton pellet granuloma and hepatic damage induced by carbon tetrachloride, respectively in rats. Apart from enzymes, non-protein sulfhydryl (NP-SH) groups were also estimated in liver. Histopathological test on liver was carried out and phenobarbitone-induced sleeping time in mice was also measured in different groups. **Results:** The phytochemical screening of the extract revealed the presence of flavonoids, tannins, sterols and or triterpenes. The extract exhibited significant protection against carrageenan-induced inflammation, cotton pellet-induced granuloma and CCl₄-induced hepatic damage. **Conclusion:** *Petroselinum crispum* exhibited significant anti-inflammatory and anti-hepatotoxic activities which merits further detailed investigations.

Key Words: Parsley, *Petroselinum crispum*, anti-inflammatory, anti-hepatotoxicity, Arab traditional medicine.

1. Introduction

The aerial parts of Parsley' *Petroselinum crispum* family Umbelliferae, locally known as Baqdunis, serve as vegetable or condiment in cookery [1]. Parsley has been claimed in Arab Traditional Medicine to possess variety of properties

including laxative, diuretic and antiurolithiatic. The leaves are used as hot application against inflammatory condition, mastitis and haematomata [2]. It is regarded as a treatment for liver ailments [3], Ahsan *et al.* [4] have

* Corresponding author
E-mail: srafat@ksu.edu.sa

reported a significant inhibitory effect of Parsley on experimentally induced kidney stone in laboratory animals. Recently, Kreydiyyeh *et al.* [5] have mentioned laxative property of Parsley. On the other hand, a diuretic effect of Parsley decoction has been determined by Kreydiyyeh and Utsa. [6]

Traditionally, Parsley leaf is used for treatment of constipation, flatulence, jaundice, colic, edema, rheumatism, diseases of prostate and liver. It has also been used as an aphrodisiac. [7]

Based on traditional use of this plant in rheumatic and liver diseases, the present study was undertaken with an objective to scientifically validate the claim.

2. Materials and methods

2.1 Plant Material

The plant material used in this study were purchased from the local market of Riyadh, Saudi Arabia and identified in the Taxonomy Division of the Medicinal, Aromatic and Poisonous Plants Research Center of this College by Dr. Atiq ur Rahman. A voucher specimen of the plant has been preserved in our herbarium.

2.2 Phytochemical Screening

Phytochemical analysis of the aerial parts of Parsley was conducted for the detection of alkaloids, cardiac glycosides, flavonoids, tannins, anthraquinones, saponins, sterols and/or triterpenes, volatile oil, cyanogenic glycosides, coumarins and glucosinolates. [8]

2.3 Animals

Wistar albino rats (180–200g) and albino mice (20–25g), of either sex were obtained from the Experimental Animal Care Center, College of Pharmacy, King Saud University in Riyadh. The animals were housed under constant temperature ($22 \pm 2^\circ\text{C}$), humidity (55%) and

light/dark cycle (12/12 h). They were provided with Purina chow and free access to drinking water *ad libitum*.

2.4 Carrageenan-induced paw edema in rats

Pedal inflammation was produced according to the method described by Winter *et al.* [9]. Carrageenan sodium salt (BDH) 1%, 0.05 mL was injected into the right hind foot of each rat under the plantar aponeurosis. The test groups of rats were treated orally with ethanolic extract of Parsley 1 or 2 g/kg body weight 1 h before the carrageenan injection.

At the same time, the control group was given 5 mL/kg of normal saline and the reference group was given 100mg/kg of an aqueous solution of oxyphenbutazone. The paw volume was measured using a plethysmometer (Apelex, France) immediately (0 h) and at 3 h after the injection of carrageenan. The inhibitory activity was calculated according to the following formula:

$$\text{Percent inhibition} = 100 [1 - (a-x/b-y)]$$

where 'b' is the mean paw volume of control rats after carrageenan injection and 'y' before the injection; whereas 'x' is the mean paw volume of treated rats before injection and 'a' is the mean paw volume after carrageenan injection.

2.5 Cotton pellet granuloma in rats

The method of Goldstein *et al.* [10] was used with a few modifications. A sterilized cotton pellet weighing 30 mg was implanted s.c. in the groin region of rats. They were treated orally with Parsley extract (1 and 2 g/kg) daily for four consecutive days. Animals in the control group received proportionate volumes of normal saline. Oxyphenylbutazone 100 mg/kg was used as the standard drug. On the fifth day, the animals were killed with ether, the pellets were removed, freed from extraneous tissues and dried overnight at 60°C and weighed.

2.6 Induction of acute hepatotoxicity by carbon tetrachloride (CCl_4)

Male Wistar rats weighing 150 g were divided into four groups of six animals each. Group I was kept as a control group. Groups II, III and IV received 0.25 ml of CCl_4 in liquid paraffin (1:1) per 100g b.wt. intraperitoneally (i.p.) [11]. Group II acted as an untreated control. Groups III and IV were treated with the extract at 1 g/kg and 2 g/kg respectively. Drug treatment was started 5 days prior to CCl_4 administration and continued till the end of the experiment. After 48 h, following CCl_4 administration animals were sacrificed using ether anaesthesia. Blood was collected by heart puncture and the plasma was separated. The liver was immediately removed, a small piece was fixed in 10% formalin and pathological changes were analysed.

2.7 Assay of plasma GOT, GPT, ALP and total bilirubin activities

The blood collected was centrifuged at 3000 rpm for 10 min to separate the plasma. The plasma was analysed for the biochemical parameters glutamic-oxaloacetic transaminase (GOT), glutamic-pyruvate transaminase (GPT), alkaline phosphatase (ALP) and total bilirubin (T.bil). [12-14]

2.8 Estimation of non-protein sulfhydryl groups (NP-SH)

Non-protein sulfhydryl groups (NP-SH) were quantified according to the method of [15]. The liver tissue was homogenized in ice-cold 0.02 M ethylenediaminetetraacetic acid (EDTA). Aliquots of 5 ml of the homogenates were mixed with 4 ml of distilled water and 1 ml of 50% trichloroacetic acid in 15 ml test tubes. The tubes were shaken intermittently for 10-15 min and centrifuged at 3000 rpm. 2 ml of supernatant were mixed with 4 ml of 0.4 M Tris buffer, pH 8.9, and 0.1 ml of 0.4% DTNB [5,5-dithio-bis- (2-nitrobenzoic acid)] was added and the

sample was shaken. The absorbance was read within 5 min of addition of DTNB at 412 nm against a reagent blank without homogenate.

2.9 Measurement of phenobarbital-induced sleeping time

The effect of ethanolic extract of Parsley on phenobarbital sleeping time in mice with carbon tetrachloride induced liver damage was investigated. The mice were fasted 18 h before each injection.

Healthy female albino mice (weight range 20-25 g) were divided into groups of ten animals each. The first group received phenobarbital 150 mg/kg intraperitoneally (i.p). The moment at which loss of righting reflex occurred was taken as the starting time for "sleep" and the end point was the moment at which the animals spontaneously regained the righting reflex. The duration of "sleep" of the first group was taken as the normal sleeping time. [16]

The second group received carbon tetrachloride given as a freshly prepared mixture with an equal volume of liquid paraffin. The duration of phenobarbital sleep was then determined 2 days after the administration of carbon tetrachloride (day 2).

All other groups received the plant extracts orally in doses of 1 and 2g/kg 1 h prior to carbon tetrachloride administration on day 0. On day 1 and on day 2, the same dose of 1 and 2g/kg of the extract was given and the duration of phenobarbital sleep was determined on the third day, 30 min after the administration of the last dose of the extract. Protection against the CCl_4 -induced liver damage was evaluated as percentage reduction in sleeping time.

2.10 Statistical analysis

The data was statistically analysed using Student's *t* - test.

3. Results

The preliminary qualitative phytochemical screening of Parsley leaves revealed the presence of flavonoids, tannins, sterols and/or triterpenes. The ethanolic extract of Parsley was found to suppress carrageenan-induced rat paw edema significantly at higher doses (2g/kg). The extract also significantly reduced the granulation tissue formation at the same high dose of 2g/kg. Although, there was a marginal decrease in edema and granulation formation at 1g/kg of Parsley extract, this reduction was not found to be statistically significant (Table 1).

Rats treated with carbon tetrachloride alone developed significant hepatocellular damage as was evident from a significant ($P < 0.001$) increase in the serum levels of oxaloacetate transaminase (GOT), glutamate pyruvate transaminase (GPT), alkaline phosphatase (ALP) and bilirubin concentration, when compared with controls. The increase was 6.1, 9.72, 1.71 and 2.1 fold for GOT, GPT, ALP and bilirubin, respectively. Pretreatment of rats with an ethanolic extract of Parsley at doses of 1 and 2g/kg markedly reduced the elevated plasma levels of these hepatospecific enzymes and serum bilirubin concentration (Table 2).

Table 1.

Effect of the Ethanolic Extract of Parsley on Carrageenan-induced paw edema and Cotton pellet granuloma in albino rats.

Treatment (n=6)	Dose mg/kg orally	Paw volume after carrageenan administration		Cotton pellets granuloma formation	
		Mean increase in paw volume (ml) 3h.	% Inhibition	Increase in pellet wt. (mg) Mean \pm S. E	% Inhibition
Control (Only Carrageenan)	-	0.58 \pm 0.037	-	53.76 \pm 2.83	-
Oxyphenylbutazone + Carrageenan	100	0.22 \pm 0.01***	62.06	23.8 \pm 3.00***	56
Parsley + Carrageenan	1000	0.50 \pm 0.02	14	46.43 \pm 2.46	14
Parsley + Carrageenan	2000	0.43 \pm 0.02**	26	41.55 \pm 1.56**	23

** $P < 0.01$, *** $P < 0.001$ Student's *t* - test as compared with control group

Table 2.

Effect of an Ethanolic Extract of Parsley on serum biochemical parameters.

Treatment (n=6)	Dose mg/kg	GOT	GPT	ALP	Bilirubin
Control	N. saline	68.73 \pm 7.10	37.01 \pm 3.46	520.33 \pm 58.88	0.586 \pm 0.045
CCl ₄		450.91 \pm 14.92*** ^a	360.83 \pm 39.39*** ^a	891.33 \pm 63.46*** ^a	1.23 \pm 0.10*** ^a
Parsley + CCl ₄	1000	437.58 \pm 20.38	276.66 \pm 14.31*** ^b	567.6 \pm 23.71*** ^b	1.03 \pm 0.03* ^b
Parsley + CCl ₄	2000	275.16 \pm 9.67*** ^b	244.08 \pm 14.07*** ^b	535.16 \pm 18.49*** ^b	0.856 \pm 0.07* ^b

* $P < 0.05$, ** $P < 0.01$, *** $P < 0.001$ Student's *t* - test; a - as compared to control group; b - as compared to CCl₄ group

A single injection of CCl_4 caused a significant reduction in hepatic NP-SH level. Pretreatment of rats with 1 and 2g/kg of Parsley extract caused a significant elevation ($P < 0.01$) in hepatic NP-SH level. Although the low dose (1g/kg) of Parsley extract, increased the liver NP-SH, the difference was not found to be statistically significant (Table 3).

Phenobarbital at a dose of 150mg/kg produced hypnosis approximately for about 41.5 min. duration. Carbon tetrachloride pretreatment increased the duration of sleep to 147.6 min. The ethanolic extract of Parsley was found to significantly inhibit the CCl_4 -induced prolongation of phenobarbital sleeping time. (Table 4)

Histopathological examination of the liver tissues provided supportive evidence for the

enzyme results. Livers from rats challenged with CCl_4 alone showed multiple foci of hepatocellular necrosis appearing mainly around central vein area and central port of the lobule alone with massive steatosis and foci of lipid loaded clean hepatocytes. Lobular foci of necrotic and steatotic hepatocytes were surrounded by histiocytic lymphocytic infiltrate. In animals pretreated with the plant extract and subsequently given CCl_4 , there was relatively well preserved cytoarchitecture around periportal tract area Fig. (1-5).

4. Discussion

Carrageenan-induced rats paw edema [9] is a suitable test for evaluating anti-inflammatory drugs and has been frequently used to assess the effects of natural products against inflammation [17-20]. This model shows proportionality

Table 3.

Effect of an Ethanolic Extract of Parsley on level of Non-protein Sulphydryls (NP-SH) on rat liver treated with CCl_4 .

Treatment (n=6)	Dose mg/kg Orally	Non-protein Sulphydryls (NP-SH) (Mean \pm S.E.) $\mu\text{mol/gm}$ of tissue
Control (normal saline)	-	1.37 \pm 0.08
CCl_4 only	-	0.91 \pm 0.05**a
Parsley + CCl_4	1000	1.05 \pm 0.06
Parsley + CCl_4	2000	1.110 \pm 0.03**b

a - as compared to control (normal saline) group; b - as compared to control (CCl_4); ** $P < 0.01$, Student's *t* - test

Table 4.

Effect of the Ethanolic Extract of Parsley on duration of Phenobarbital-induced sleeping time of mice treated with carbon tetrachloride

Treatment (n=10)	Dose mg/kg	Sleeping-time (mice)	Reduction in sleeping-time
Phenobarbital	150	41.5 \pm 1.376	-
CCl_4 + Phenobarbital	-	147.6 \pm 5.70 *a	-
Parsley + Phenobarbital	1000	109.9 \pm 3.77 *b	25.5%
Parsley + Phenobarbital	2000	88.8 \pm 4.37*b	39.8%

* $P < 0.001$ Student's *t* - test; a-as compared to only Phenobarbital group; b-as compared to CCl_4 + Phenobarbital group.

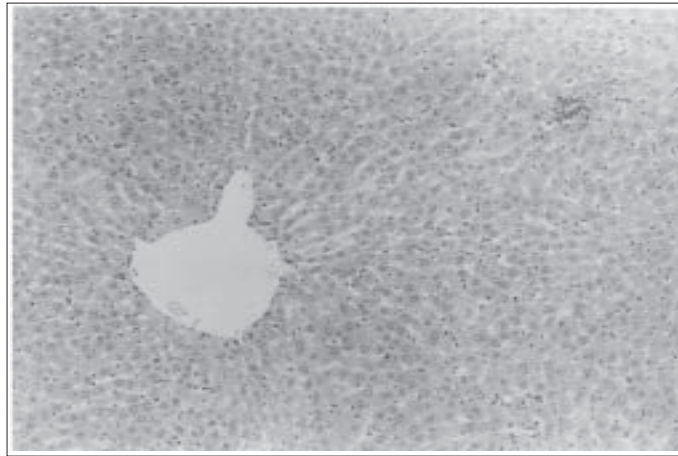


Fig. 1. Histological appearance of normal rat liver lobule-note regular outline of lobular central vein and regular cords of hepatocytes with a scattered lymphoid and endothelial kupfer cells within the sinuses H. & E. 200x.

Fig. 2. Histological appearance of rat liver exposed to CCl_4 only. Multiple foci of hepatocellular necrosis appear mainly around central vein area and central part of lobule along with massive steatosis and of foci of lipid loaded clear hepatocytes. H. & E. 200x

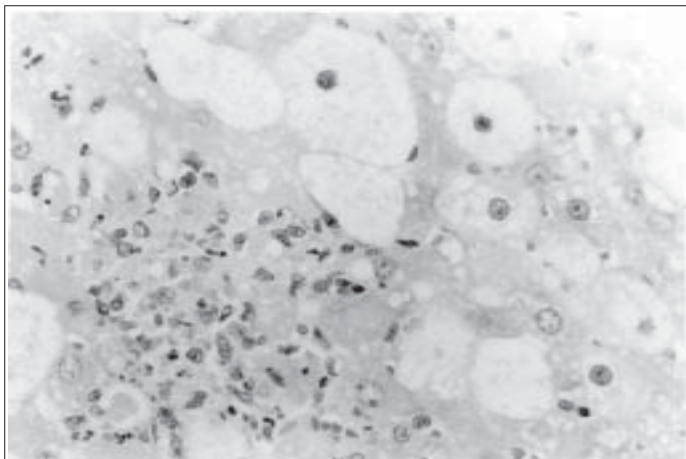
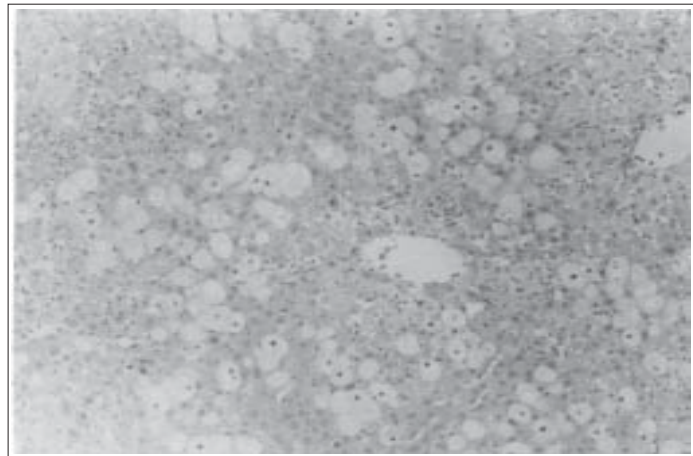


Fig. 3. Histological appearance of rat liver exposed to CCl_4 only. Lobular foci of necrotic and steatotic hepatocytes are surrounded by histocytic and lymphocytic infiltrate. H. & E. 400x

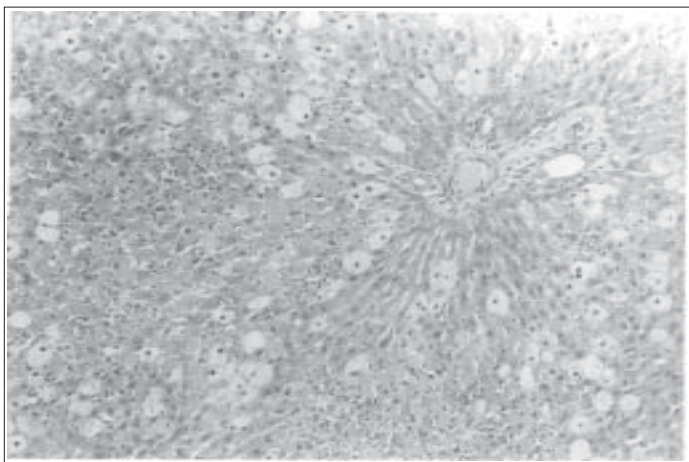
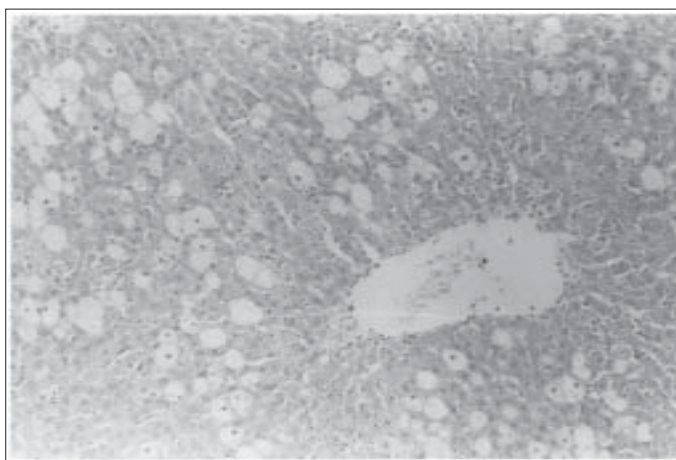


Fig. 4. Histological appearance of rat liver treated with 1g/kg of parsley extract + CCl₄. Periportal tract area - note relatively well preserved cytoarchitecture around but still conspicuous number of necrotic foci and steatotic hepatocytes confined to intermediate lobular zone. H. & E. 200x.

Fig. 5. Histological appearance of rat liver treated with 2g/kg parsley extract + CCl₄. Hepatic lobular with central vein displayed persistent multifocal hepatic lobular necrosis confined to the vicinity of central vein H. & E. 200x.



between laboratory test dose and clinical dose [21]. Carrageenan-induced acute inflammation is believed to be biphasic. The first phase is due to the release of histamine and serotonin; the second phase is caused by the release of bradykinin, protease, prostaglandin and lysosome [22] and some other mediators eg. Leukotrienes, PAF. It has been reported that the second phase of edema is sensitive to most clinically effective anti-inflammatory agents [23]. Parsley extract significantly inhibited the edema formation after 3 h of administration.

Furthermore, it was observed that the extract significantly reduced the granuloma formation in rats. Multiplication of small blood vessels as well as proliferation of fibroblasts are the characteristic features at the repair phase of inflammation. Such proliferating cells penetrate the exudate, producing a highly vascularized reddened mass known as granulation tissue [24]. The Parsley extract effectively reduced the cotton pellet granuloma suggesting its activity in the proliferative phase of the inflammation process.

The efficacy of any hepatoprotective drug is essentially dependent on its capability to either reduce the harmful effects or to maintain the normal hepatic physiological mechanism which have been unbalanced by the hepatotoxin. The results of the present study revealed that the ethanolic extract of Parsley possesses significant hepatoprotective effect against experimental CCl₄-induced liver damage in animals.

The elevation in the plasma levels of cytoplasmic and mitochondrial enzymes accurately reflects liver injury induced with CCl₄ [25]. Such increase in the levels of certain enzymes (GOT, GPT) under the influence of CCl₄ have been attributed to the disturbed or damaged structural integrity of the liver [26]. Significant decreases of the CCl₄-induced elevated GOT and GPT level by the Parsley extract definitely suggests protection of the structural integrity of the hepatocyte cell membrane by the extract.

The increased level of the plasma alkaline phosphatase is another measure of liver damage occurring due to the *de novo* synthesis by the liver cells [27]. In the present study it was observed that on treatment with the Parsley extract, there was a significant decrease in plasma alkaline phosphatase level indicating the ability of the extract to maintain the normal level. This effect might be due to either a decrease in *de novo* synthesis or by a feedback mechanism.

On the other hand, the Parsley extract was capable of lowering the plasma bilirubin level thereby indicating its effectiveness in maintaining the normal functional status of the liver.

In addition, phenobarbital-induced sleeping time was significantly prolonged in liver damage and this parameter may be employed as a measure of the functional status of the hepatic drug metabolizing system [28-30].

Histopathological analysis are in good agreement with biochemical changes. The chemical constituents of Parsley, responsible for its anti-inflammatory and hepatoprotective activities are not known.

However, Parsley contains a number of chemical components, including, flavonoids, tannins, sterols and/or triterpenes; and all of these constituents are known to exhibit antioxidant activity and offer protection against cell damage [31], and possess free radical scavenging effects. Furthermore, CCl₄ caused a significant reduction in non-protein Sulfhydryl (NP-SH) concentration. Parsley extract, however, significantly replenished the NP-SH concentration. Thus role of sulfhydryl groups seems to be involved in hepatoprotective mechanism.

On the basis of above results, it could be concluded that Parsley exhibited significant anti-inflammatory activity and a significant hepatoprotection against CCl₄-induced toxicity. Further experiments are necessary to isolate the active principles of the Parsley and to establish its chemical nature which are responsible for their observed properties.

5. Acknowledgement

The authors are grateful to Mr. Malik Sawood Ahmed for his technical assistance.

References

1. Duke JA. (1989) *CRC Handbook of Medicinal Herbs*, CRC Press Inc.: Boca Raton; 365-367.
2. Leung, YA. (1988) *Encyclopedia of Common Natural Ingredients Used in Food, Drug and Cosmetics*, John Wiley & Sons: New York; 257-259.
3. Anonymous (1983) *British Herbal Pharmacopoeia*. The British Herbal Medicine Association: Lane House, West Yorks; 154-155.
4. Ahsan SK, Shah AH, Tanira MOM, Ahmed MS, Tariq M, Aqeel AM. (1990) *Fitoterapia* 51(5): 495-498.
5. Kreydiyyeh SI, Utsa J, Kaouk I, Al-Sadi R. (2001) *Phytomedicine* 8(5): 382-388.
6. Kreydiyyeh SI, Utsa J. (2002) *J. Ethnopharmacol.* 79(3) : 353-357.
7. Anonymous (2000) *Natural Medicine Comprehensive Database*. Therapeutic Research Faculty, Stockton: CA.; 800-801.
8. Farnsworth NR. (1966) Biological and Phytochemical Screening of Plants. *J. Pharm. Sci.* 55(3): 225.
9. Winter CA, Risley EA, Nuss GW. (1962) *Proc. Soc. Exp. Biol. Med.* III: 544-547.
10. Goldstein SA, Shemano I, Daweo R, Betler JM. (1967) *Arch. Int. Pharmacodyn. Ther.* 165: 249-301.
11. Nishigaki I, Kuttan R, Oku H, Ashoori F, Abe H, Yagi K. (1992) *J. Clin. Biochem. Nutr.* 13: 23-29.
12. Reitman S, Frankel S. (1957) *Am. H. Clin. Patho.* 28: 56-63.
13. Szasz G. (1971) *Zeitsch. Kinderheil.* III: 233.
14. Jendrassik L, Graff P. (1938) *Biochem. J.* 297: 81-89.
15. Sedlak, J. Lindsay RH. (1968) *Anal. Biochem.* 25; 192-205.
16. Van Puyvelde, Kayonga A, Brioen P, Costa J, Ndimubakunzi A, dekempe N, Schamp N. (1989) *J. Ethnopharmacol.* 26: 121-127.
17. Della Laggia A, Tubaro A, Dri P, Zilli C, Del Negro P. (1986) *Clin. Biol. Res.* 231 : 481-488.
18. Alcaraz MJ, Fernandiz ML. (1987) *J. Ethnopharmacol.* 21 : 209-299.
19. Alcaraz MJ, Jimenez MJ, Valverde S, Sanz J, Rabanal RM, Villar AM. (1989) *J. Nat. Prod.* 52 : 1088-1091.
20. Fernandiz ML, Alcaraz MJ. (1991) *Agents Actions* 32 : 283-288.
21. Otterness IG, Gans DL. (1988) *J. Pharm. Sci.* 77: 790-795.
22. Castro H, Sasame H Sussman H, Bullette P. (1968) *Life Sci.* 7: 129-136.
23. Smucker E, Arrhenius E, Hultin T. (1967) *J. Biochem.* 103: 55-64.
24. Swingle KT. (1974) In: RS. Scherrer, MW White House (Eds.) *Anti-inflammatory Agents: Chemistry and Pharmacology*, Vol. 2, Academic Press: New York; 34-122.
25. Zimmerman H, Kodera Y, West M. (1965) *J. Lab. Clin. Med.* 66: 315.
26. Chenoweth MB, Hake CL. (1962) *Annu. Pharmacol.* 2: 363-398.
27. Recknagel RD, Glende EA, Ugajio G, Koch KR, Srinivasan S. (1973) *Int. Symp. Hepatotoxic.* Academic Press: New York; 7.
28. Fujimoto JM, Pearce KB, Plaa GL. (1960) *J. Pharmacol. Exp. Ther.* 129: 139-143.
29. Brauer RW, Root WA. (1946) *J. Pharmacol. Exp. Ther.* 88: 109-118.
30. Vogel G. (1977) In: H. Wagner and Wolff. (Eds.) *New Natural Products and Plant Drugs with Pharmacological, Biological or Therapeutic activity*, Springer-Verlag. 249-256.
31. Kikuzaki H, Hara S, Kawai Y, Natakani N. (1999) *Phytochemistry* 52(7): 1307-1312.