

See discussions, stats, and author profiles for this publication at: <https://www.researchgate.net/publication/299350330>

# The protective effect of *Coriandrum sativum* L. oil against liver toxicity induced by Ibuprofen in rats

Conference Paper · January 2016

CITATIONS

0

READS

399

4 authors, including:



**Hoda H Baghdadi**

Institute of graduate studies and research, Alexandria University Egypt, Alexandria.

25 PUBLICATIONS 705 CITATIONS

[SEE PROFILE](#)



**Fatma El-Demerdash**

Alexandria University

43 PUBLICATIONS 2,625 CITATIONS

[SEE PROFILE](#)



**Eman Hashem Radwan**

Damanhour University

38 PUBLICATIONS 40 CITATIONS

[SEE PROFILE](#)

Some of the authors of this publication are also working on these related projects:



Toxicity of nanoparticles. [View project](#)



Sustainability of Agricultural Environment in Egypt-I and II, Contributed Book published by Springer International Publishing during late 2018 or early 2019 [View project](#)



# JBSAR



Journal of Bioscience and Applied Research

WWW.JBSAR.com

## The protective effect of *Coriandrum sativum* L. oil against liver toxicity induced by Ibuprofen in rats

Hoda H. Baghdadi<sup>1</sup>, Fatma M.El-Demerdash<sup>2</sup>, Eman H. Radwan<sup>3</sup>, Sodfa Hussein<sup>4</sup>

<sup>1,2,4</sup>Department of Environmental Studies, Institute of Graduate Studies and Research, Alexandria University.

<sup>3</sup>Zoology Department, Faculty of Science, Damanshour University.

(Corresponding author Email: dr\_eman\_hashem@yahoo.com)

### Abstract

Ibuprofen (IBU) is a Non-steroidal anti-inflammatory drug used in the treatment of pain, fever and inflammation. *Coriandrum sativum* is cultivated for its aromatic and medicinal uses. The present study aims to evaluate the protective effect of *Coriandrum sativum* volatile oil on hepatotoxicity of IBU in rats. Five groups of albino rats were used. Group I (control), group II (*C. sativum* oil, 40 mg/kg B.W. for 14 day), group III (IBU group, 100mg/kg bodyweight B.W., for 14 day), group IV (IBU+ *C. sativum* oil) and group V (recovery group). The activity of alanine aminotransferase (ALT) and aspartate aminotransferase (AST) were measured in the liver of different groups addition to the histological examination of the sections of liver. The results showed that IBU caused a significant decrease in the activity of ALT and AST in the liver. The histological examination of the liver showed many pathological changes. Administration of coriander volatile oil in the combination with IBU was able to significantly increase the activity of both AST and ALT, in the liver and caused a significant decrease in the deleterious effect induced by IBU. The present results confirm that the antioxidant activity of volatile oil of the *Coriandrum sativum* L., against hepatotoxicity of IBU.

**Keywords:** Ibuprofen, liver, *Coriandrum sativum*, Histopathology, Transaminases

### 1 Introduction

Ibuprofen (IBU) is used mostly for the inflammatory diseases such as rheumatoid arthritis, menstrual cramps, toothache, and dysmenorrhea (Chen *et al.*, 2005; Mahalakshmi *et al.*, 2010). Ibuprofen has the same action as

that of aspirin and shares the same side effects to a lesser extent (Thangapandian, 2012). IBU has been used through different traditions and considered to have cooling, stimulant, carminative, digestive properties, cystitis (Aboelsoud, 2010), headaches, measles, rectal prolapse, prevent cancer (Li and Ben, 1999), relief of anxiety and insomnia, and may have potential sedative, hypotensive, and muscle relaxant effects (Emamghoreishi *et al.*, 2005), diuretic, antipyretic, stomachic, aphrodisiac, laxative and anthelmintic properties (Deepa and Anuradha, 2011). On the other hand, Ibuprofen was commonly known to produce hepatotoxicity, inducing cholestatic hepatitis (Manov *et al.*, 2006). Besides, ibuprofen was also found to be most active in impairing gluconeogenesis from lactate, and in impairing albumin synthesis in vitro (Castell *et al.*, 1988). Lower dose of ibuprofen also induces more histopathological lesions in rats' liver than chlorpromazine, paracetamol and other (Schoonen *et al.*, 2007). Various theories have been proposed for the mechanism by which ibuprofen damages the liver (Teoh and Farrell, 2003). It was reported to cause changes in the architecture of the hepatic cell, cell permeability and to create ionic imbalance resulting in increased intracellular calcium concentration. Consequently, mitochondrial activity was inhibited, leading to the death of hepatic cells (Saraf *et al.*, 1994).

Plants, including herbs and spices, have many phytochemicals which are the potential source of natural antioxidant, e.g.; flavonoids, alkaloids, tannins and phenolic acids. Natural antioxidants are known to protect cells from damage induced by oxidative stress, which is generally considered to be a cause of aging, degenerative diseases, and cancer (Ringman *et al.*, 2005). The health promoting effects of antioxidants from plants and spices are thought to arise from their protective effects by counteracting reactive oxygen species. Coriander

(*Coriandrum sativum* L.) is of economic importance since it has been used as a flavoring agent in food products and drugs. This medicinal plant widely distributed and mainly cultivated for the seeds which contain an essential oil (ranges between 0.3% and 1.1%) (Neffati *et al.*, 2011). The essential oil and various extracts from coriander have been shown to possess antibacterial, antidiabetic, anticancerous, antimutagenic, antioxidant and free radical scavenging activities (Zoubiri and Baaliouamer, 2010). Coriander is known for its wide range of healing properties. It is generally used in gastrointestinal complaints such as anorexia, dyspepsia, flatulence, diarrhea, griping pain and vomiting. Coriander fruit is also reputed as refrigerant, tonic, diuretic and aphrodisiac, while, the oil is considered useful in flatulent colic, rheumatism, and neuralgia. Coriander is used as antiedemic, anti-inflammatory, antiseptic, antihypertensive, lipolytic and myorelaxant, and possesses nerve-soothing property (Darughe *et al.*, 2012). Coriander has also been reported to exhibit several pharmacological effects such anti-mutagenic activity, cholesterol lowering activity, hepatoprotective activity and in detoxification (Momin *et al.*, 2012). The present study aims to evaluate the protective effect of *Coriandrum sativum* volatile oil on ibuprofen induced hepatotoxicity in rats.

## 2 Materials and Methods

### Isolation of volatile oil of *C. sativum*:

*Coriandrum sativum* L. is a small size fruit, was purchased from the local markets and the specimens were further authenticated in the herbarium of the Faculty of Science, Alexandria University, Egypt. A Clevenger-type apparatus was used for essential oil extraction. The essential oil was isolated from the full dried coriander fruits. About 100 gm seeds for each treatment were set in a round bottom flask with distilled water (1000 ml), enough to cover the coriander fruits. The process of hydro distillation lasted 4 consecutive hours. The isolated essential oil was collected and stored at 4°C until analyzed and used (Clevenger type, 1928).

### Experimental design:

Eighty male Albino rats weighing 150–160gm. were obtained from the animal house of the Faculty of Medicine, Alexandria University. Animals were handled in accordance with the principles of laboratory animal care. They were housed in a clean and well ventilated animal house with a constant 12 hours light and 12 hours dark schedule. Clean water ad libitum and pellet diet were given freely. After two weeks of acclimatization, rats were randomly divided into two 5 groups:

Group I (is the control group): Rats received DMSO orally for fourteen consecutive days. Group II (is the coriander volatile oil group): Rats received coriander volatile oil at a

dosage of (40 mg/kg B.W. orally) for fourteen consecutive days (Abou El-Soud *et al.*, 2012).

Group III (the Ibuprofen group): Rats were treated orally with Ibuprofen dissolved in 0.9% saline. Rats received Ibuprofen at a dosage of 100mg/kg bodyweight (B.W.), orally for fourteen consecutive days (Garba *et al.*, 2012). Ibuprofen (Brufen @ 600) was purchased from Kahira Pharm. & Chem. Ind.Co

Group IV (the Ibuprofen+Coriander volatile oil group): Rats received coriander volatile oil at a dosage of 40 mg/kg body weight, followed by Ibuprofen at a dosage of 100mg/kg B.W orally for fourteen consecutive days.

Group V (is the Ibuprofen withdrawal group): rats were treated orally with Ibuprofen dissolved in 0.9% saline solution. The rats received Ibuprofen at a dosage of (100mg/kg B.W. orally) for fourteen consecutive days. Ibuprofen treatment was withdrawn for a period of fourteen days after fourteen days of treatment period .

### Biochemical and histological preparation:

Twenty four hours after the last treatment schedule, the animals were sacrificed by decapitation. For biochemical analysis, the liver was removed and washed in 0.9% saline solution then stored at -20°C. Liver alanine aminotransferase (ALT) and aspartate aminotransferase (AST) activity was determined using the method of Reitman and Frankel (1975). For histological study, the liver of the different groups were immediately fixed in 10% formalin saline solution. Paraffin sections 5 µm thick were stained with haematoxylin and eosin (Drury and Wallington, 1980).

### Statistical analysis:

Statistical analysis was performed using one way ANOVA, using Statistical Product and Service Solutions (SPSS, 2010) program produced by Statistical Analysis Systems Institute. Significant differences among means were evaluated at  $p < 0.05$ .

## 3 Results

### Biochemical results:

The present results presented in Table (1) revealed that a significant ( $p < 0.05$ ) decrease in liver transaminases, in the treatment group, in both groups (group 3 and group 4) treated with IBU when compared with the control group, whereas group 4 which was treated with coriander oil and IBU revealed a significant ( $p < 0.05$ ) increase in both AST and ALT activities when compared to group 3 which was treated only with IBU, on the other hand, group 2 which was treated only with coriander oil revealed a significant ( $p < 0.05$ ) increase when compared to control group. Liver transaminases activities were found to be significantly ( $p < 0.05$ ) increased in the animals after withdrawal of ibuprofen.

Table (1): The changes in aspartate aminotransferase (AST), alanine aminotransferase (ALT) activities in liver of male rats treated with ibuprofen (IBU), coriander oil and their combination after treatment and recovery periods.

Groups	Doses administered		Parameters measured	
	Ibuprofen (mg/kg)	Coriander volatile oil (mg/kg)	AST (U/mgprotein)	ALT (U/mg protein)
<b>Treatment group</b>				
I(control )	0	0	122±1.24 <sup>b</sup>	163±4.59 <sup>b</sup>
II(Coriander oil)	0	40	141±2.55 <sup>a</sup>	189±6.12 <sup>a</sup>
III(IBU)	100	0	76.91±1.72 <sup>d</sup>	102±2.20 <sup>d</sup>
IV(IBU+Coriander)	100	40	109±1.22 <sup>c</sup>	131±2.40 <sup>c</sup>
V(IBU ) recovery	0	0	106±3.39 <sup>c</sup>	134±2.22 <sup>c</sup>

Abcd: Mean values within a row not sharing common superscript letters were significantly different,  $p < 0.05$ . Values are expressed as means  $\pm$  S.E. (n = 7 for each group).

### Histological observations:

The histological examinations of the liver sections are represented in Figures (1-5). In Figure 1 showed that liver of the control rats receiving DMSO orally showing normal hepatocytes, sinusoids and central vein. The hepatocytes were neatly arranged in anastomosing plates with the sinusoids radiating from the central vein. Animals received 40 mg/kg of coriander volatile oil orally showing normal histological structure of the liver including normal hepatocytes, sinusoids and central vein (Fig.2). Animals receiving 100mg/kg ibuprofen orally showing dilation and congestion of blood vessel, area of necrosis, and wide spread areas of vacuolar degeneration (Fig.3a,b). Animals treated with 100mg/kg ibuprofen+40 mg/kg of the coriander volatile oil showed normal architecture including normal hepatocytes, sinusoids, and central vein (Fig.4). Animals with withdraw of ibuprofen still showing congested blood vessels (Fig.5).

### 4 Discussion

The present results declared that AST and ALT decreased in liver of IBU-treated rats. The decrease in liver AST and ALT is useful in indicating the existences of liver diseases as this enzyme is present in large quantities in liver, it increased in plasma and decreased in liver when cellular damage or degeneration occurs in this organ (Hassoun and Stohs,1995). The decline of these enzymes is an

indicative of IBU toxicity and indication of possible hepatocellular damage that could exert through alterations in liver functions. These findings are in agreement with the previous studies done by Garba *et al.* (2012) in which plasma AST and ALT activities showed significant increase in the ibuprofen (100mg/kg) treated rats. The reduction in transaminases may be due to tissue damage, alterations of the permeability of cell membrane (Farage *et al.*, 2010). Aprioku *et al.* (2014) studied the effects of ibuprofen (20 and 40 mg/kg) on hepatic, renal, and hematological indices in relation to dose and duration of exposure. They reported that the elevation in serum levels of alanine transaminase (ALT) and alkaline phosphatase (ALP) by ibuprofen in their study was indicative of cellular injury to the liver. Aspartate aminotransferase (AST) was also increased dose- and time-dependently, although not significantly. ALT was affected only after 28 days of exposure of the high dose of ibuprofen (40 mg/kg) used in their study, the effect of ibuprofen on liver function was correlated positively with the dose and duration of exposure.

Histological results revealed that IBU induced several histopathological alterations in liver of rats. Similarly, Senthilkumar *et al.*, (2013) reported that the administration of ibuprofen (500 mg/kg B.W.) produced significant changes in the normal hepatic cells, resulting in

the formation of centrilobular necrosis, vacuolization, and hepatomegaly. Ibuprofen was commonly known to produce hepatotoxicity, inducing cholestatic hepatitis (Manov *et al.*, 2006). Low dose of ibuprofen induces more histopathological lesions in rats' liver than chlorpromazine, paracetamol and other (Schoonen *et al.*, 2007). Ibuprofen was reported to cause changes in the architecture of the hepatic cell, cell permeability and to create ionic imbalance resulting in increased intracellular calcium concentration. Consequently, mitochondrial activity was inhibited, leading to the death of hepatic cells (Saraf *et al.*, 1994). Hepatic necrosis induced by ibuprofen is usually associated with elevated levels of liver marker enzymes which is due to the cellular leakage and loss of functional integrity of the cell membrane in liver (Reitman and Frankel, 1957).

Treating animals with IBU and coriander oil caused ameliorative effect in IBU-induced hepatotoxicity. Transaminases, hepatic ALT and AST increased with decrease of histopathological changes. These results are similar to the results obtained by Samojlik *et al.* (2010) who found that *C. sativum* oil had protective effect against CCl<sub>4</sub> -induced hepatotoxicity. They added that this effect is due to the antioxidant activity of *C. sativum*. The antioxidant effect of *C. sativum* was reported by some investigators. Chithra and Leelamma, (1999) confirmed activation of antioxidant enzymes (catalase, glutathione peroxidase) in rats treated by *Coriandrum sativum*. Abou El-Soud *et al.* (2012) reported that the reduced level of the enzyme glutathione peroxidase as a result of induction of diabetes was significantly elevated above the normal control level ( $p < 0.05$ ) after treatment with coriander oil.

Sriti *et al.* (2011) demonstrated that the chemical class characters of *C. sativum* EOs from different fruit samples

were monoterpene hydrocarbons ranged between 16.2% to 20.7%, monoterpene alcohols ranged between 59.4% to 73.8%, monoterpene esters ranged between 3.7% to 9.1%, aldehydes ranged between 0.3% to 0.9%, ketones ranged between 3% to 6.5% ; and phenols about 0.06%). The raw coriander contained mainly of linalool (72.7%) followed by l-terpinene (8.8%),  $\alpha$ -pinene (5.5%), camphor (3.7%), limonene (2.3%), geranyl acetate (1.9%) and p-cymene (1.5%) (Mageed *et al.*, 2012). Coriander (*Coriandrum sativum* L.) volatile oil is rich in beneficial phytonutrients and have been qualified as natural antioxidants. The main components of the essential oil are camphor (44.99%), cyclohexanol acetate (cis-2-tert-butyl-) (14.45%), limonene (7.17%) and  $\alpha$ -pinene (6.37%). Darughe *et al.* (2012) showed that coriander essential oil at percentage of 0.05, 0.10 and 0.15 was very much effective in inhabiting primary and secondary oxidation products. It was found that at the proportion of 0.02%, its effects were almost equal to BHA (butylated hydroxyanisole). Shahwar *et al.* (2012) showed that the coriander seed essential oil had significant radical scavenging activity in comparison with coriander leaf essential oil. Sriti *et al.* (2011) reported that the methanolic extracts of coriander fruits showed better antioxidant activity than EOs and the 2,2 - diphenyl -1-picrylhydrazyl (DPPH). Radical scavenging activity scavenging ability of methanolic extracts of coriander fruits was higher than that of synthetic antioxidant butylated hydroxy toluene (BHT) which IC<sub>50</sub> equal 25 mg/ml. It is concluded from the present work coriander volatile oil treatment minimized and alleviated the hazardous effects IBU and this may be attributed to the vital role of coriander oil active ingredients as antioxidant.

## 5 References

- Abo-El-Soud, N.H., (2010). Herbal medicine in ancient Egypt. *J. Medicinal Plants Research*, 4(2): 082-086.
- Abou El-Soud, H. N., El-Lithy, A. N., El-Saeed, M. S. G., Wahby, S. M., Khalil, M. Y., Abou El-Kassem, T. L.; Morsy, F. and Shaffie, N. (2012). Efficacy of *Coriandrum sativum* L. essential oil as antidiabetic. *J. Applied Sciences Research*, 8(7): 3646-3655.
- Aprioku, J. S., Nwidu, L. L. Amadi, C. N. (2014). Evaluation of toxicological profile of ibuprofen in Wistar albino rats. *Am. J. Biomed. Sci.* 6(1): 32- 40.
- Chithra, V. and Leelamma, S. (1999). *Coriandrum sativum* changes the levels of lipid peroxides and activity of antioxidant enzymes in experimental animals. *Indian J. Biochemistry and Biophysics*, 36: 59-61.
- Castell, J. V.; Larrauri, A., Gómez-Lechón, M. J. (1988). A study of the relative hepatotoxicity in vitro of the non-steroidal anti-inflammatory drugs ibuprofen, flurbiprofen and butibufen. *Xenobiotica*, 18: 737-745.
- Chen, H., Jacobs, E., Schwarzschild, M., McCullough, M., Calle, E., Thun, M., Ascherio, A. (2005). Non-steroidal anti-inflammatory drug use and the risk for Parkinson's disease. *Ann Neurol.*, 58 (6): 963.
- Deepa, B. and Anuradha, C.V. (2011). Anti-oxidant potential of *Coriandrium sativum* L. seed extract. *Ind. J. Exp. Biol.*, 49: 30–38
- Darughe, F.; Barzegar, M., Sahari, M. A. (2012). Antioxidant and antifungal activity of Coriander (*Coriandrum sativum* L.) essential oil in cake. *Int. Food Res. J.*, 19(3): 1253-1260.
- Drury, R. V. A. and Wallington, E. A. (1980). Carlton's histological techniques. 5th ed, Oxford University Press: New York, Pronto.
- Emamghoreishi, M., Khasaki, M., Aazam, M. F. (2005). *Coriandrum sativum*: Evaluation of its anxiolytic effect in the elevated plus-maze. *J. Ethnopharmacology*, 96: 365–370.
- Farage, A. G. A., Elhalwagy, M. E. A., Farid, H. E. A. (2010). Effect of ginger supplementation on developmental toxicity induced by fenitrothion insecticide and/or lead in albino rats. *Pest Biochem Phyziol*; 97: 267-274.
- Garba, A. M.; Mohammed, B.; Garba, S. H.; Numan, A. I.; Dalori, B. M. (2012). The effects of honey and *Aloe vera* extract on ibuprofen induced liver damage in rats. *IOSR-JPBS*, 3(2): 2278-3008.

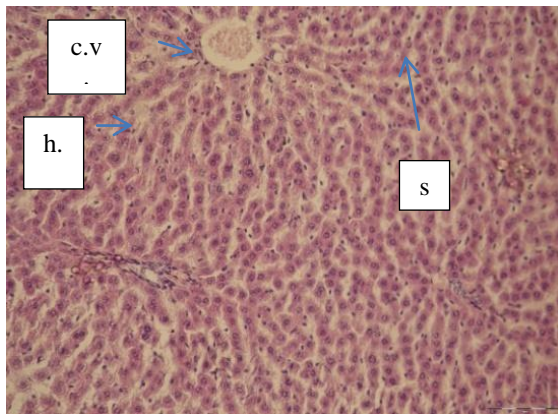


Figure (1): Photomicrograph of of a control rat liver showing: normal hepatocytes (h.), sinusoids (s.) and central vein (c.v.), H & E;X: 200

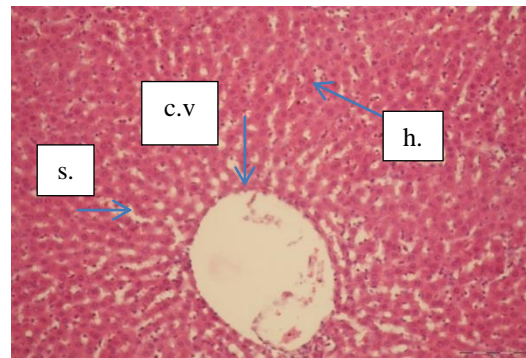
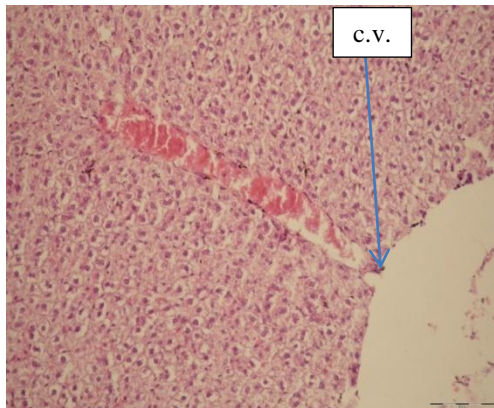
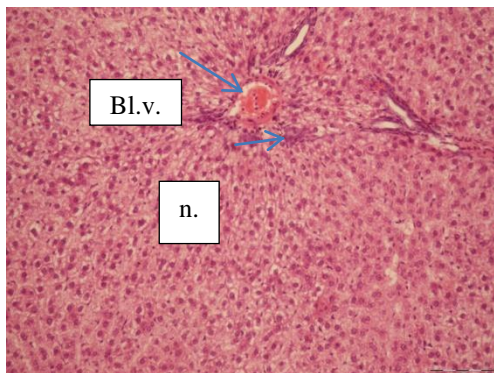


Figure (2): Photomicrograph of rat liver treated with 40mg/kg coriander volatile oil showing: normal hepatocytes (h.), sinusoids (s.) and central vein (c.v), H & E;X: 200.



(3a)



(3b)

Figure (3a, b): Photomicrographs of rats liver treated with 100mg/kg ibuprofen showing: dilation of blood vessel (c.v.),congested portal vein, necrosis (n.)and wide spread areas of vacuolar degeneration, H & E;X: 200.

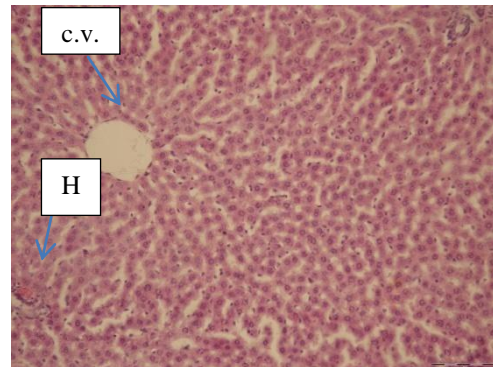


Figure (4): Photomicrograph of a rat liver treated with 100mg/kg ibuprofen +40mg/kg coriander volatile oil showing normal arrangement of the hepatocytes(H)and central vein (c.v.) ( H & E;X: 200.

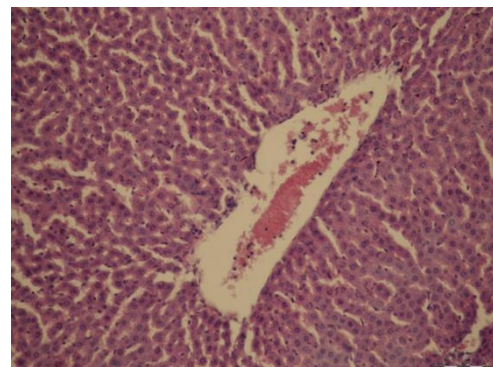

Figure (5): Photomicrograph of a rat liver after withdrawn of showing congested and enlarged central vein (H & E;X: 200).

- Hassoun, E. A., Stohs, S. J. (1995). Comparative studies on oxidative stress as a mechanism for the fetotoxicity of TCDD, endrin and lindane in C57BL/6J and DBA/2J mice. *Teratol.*, 51: 186.
- Li, S.Z., Ben C. M. (1999). Chinese Archives Publishing House, Beijing.
- Mageed, M.A.A.E, Mansour, A.F., Massry, K.F.E., Ramadan, M., Shaheen, M.S.; Shaaban, H. (2012). Effect of microwaves on essential oils of coriander and cumin seeds and on their antioxidant and antimicrobial activities. *J. Essent Oil Bear Plants*, 15: 614-27
- Mahalakshmi, R., Rajesh, P., Ramesh, N., Balasubramanian, V., Rajesh Kannan, V. (2010). Hepatoprotective activity on Vitexnegundo Linn. (Verbenaceae) by using Wistar Albino Rats in Ibuprofen induced model. *International J. Pharmacology*, 6(5): 658–663.
- Manov, I., Motanis, H., Frumin, I., Iancu, T. (2006). Hepatotoxicity of anti-inflammatory and analgesic drugs: ultrastructural aspects. *Acta Pharmacol. Sin.*, 27: 259–272.
- Momin, A. H., Acharya, S. S., Gajjar, A. V. (2012). *Coriandrum sativum*- review of advances in phytopharmacology. *IJPSR*, 3: 1233-1239.
- Neffati, M., Sriti, J., Hamdaoui, G., Kchouk, M. E., Marzouk, B. (2011). Salinity impact on fruit yield, essential oil composition and antioxidant activities of *Coriandrum sativum* fruit extracts. *Food Chemistry*, 124: 221–225.
- Reitman, S. and Frankel, S. (1957). Colorimetric method for the determination of serum glutamic oxalacetic and glutamic pyruvic transaminases. *Am. J. Clin. Pathol.*, 28(1): 56-63.
- Ringman, J. M., Frautschy, S. A., Cole, G. M., Masterman, D. L., Cummings, J. L. (2005). Potential role of the curry spice curcumin in Alzheimer's disease. *Curr. Alzheimer Res.*, 2: 131-136.
- Sriti, J., Wannes, W. A., Talou, T., Vilarem, G., Marzouk, B. (2011). Chemical composition and antioxidant activities of Tunisian and Canadian coriander (*Coriandrum sativum* L.) fruit. *J. Essent. Oil Res.*, 23: 7-15.
- Shahwar, M. K., El-Ghorab, A. H., Anjum, F. M., Butt, M. S., Hussain, S., Nadeem, M. (2012). Characterization of Coriander (*Coriandrum sativum* L.) Fruits and Leaves: Volatile and nonvolatile Extracts. *International J. Food Properties*, 15: 736-747 .
- Samojlik, I., Lakić, N., Mimica-Dukić, N., Đaković-Švajcer, K., and Božin, B. (2010). Antioxidant and hepatoprotective potential of essential oils of coriander (*Coriandrum sativum* L.) and caraway (*Carum carvi* L.) (Apiaceae). *J. Agric. Food Chem.*, 58 (15):8848–8853
- Saraf, S., Dixit, V. K., Tripathi, S. C., Patnaik, G. K. (1994). Antihepatotoxic activity of *Cassia occidentalis*. *International J. Pharmacognosy*, 32(2): 38-183.
- Schoonen, W. G., Kloks, C. P., Ploemen, J. P., Smit, M. J., Zandberg, P., Horbach, G. J., Mellema, J. R., Thijssen-Vanzuylen, C., Tas, A. C., van Nesselrooij, J. H., Vogels, J. T. (2007). Uniform procedure of (1) H NMR analysis of rat urine and toxicometabonomics Part II: comparison of NMR profiles for classification of hepatotoxicity. *Toxicol. Sci.*, 98: 286-297.
- Senthilkumar, B., Jayavelu, A., Natarajan, A., Sundaresan, S., Devi, K. (2013). Hepatoprotective activity of *Boerhavia Diffusa* Linn. (Nyctaginaceae) against Ibuprofen induced hepatotoxicity in Wistar albino rats. *International J. Pharma Research and Review*, 2(4): 1-8.
- Teoh, N. C. and Farrell, G. C. (2003). Hepatotoxicity associated with non-steroidal anti-inflammatory drugs, *Clin. Liver Dis.*, : 401-413.
- Thangapandian, K. (2012). Ibuprofen Induced Nephrotoxicity in Adult Albino Rats. *IJALS*, 1: 58-67.
- Zoubiri, S. and Baaliouamer, A. (2010). Essential oil composition of *Coriandrum sativum* fruit cultivated in Algeria as food grains protectant. *Food Chem.*, 122: 1226-1228.