



Protective effects of *Coriandrum sativum* extracts on carbon tetrachloride-induced hepatotoxicity in rats

S. Sreelatha^{a,*}, P.R. Padma^b, M. Umadevi^a

^a Department of Chemistry and Biosciences, SASTRA University, SRC Campus, Kumbakonam 612 001, Tamilnadu, India

^b Department of Biochemistry and Biotechnology, Avinashilingam University, Coimbatore, India

ARTICLE INFO

Article history:

Received 18 January 2008

Accepted 17 December 2008

Keywords:

Coriandrum sativum
Carbon tetrachloride
Hepatotoxicity
Oxidative stress
Protective effect

ABSTRACT

Oxidative damage is implicated in the pathogenesis of various liver injuries. The study was aimed to investigate the antioxidant activity of *Coriandrum sativum* on CCl₄ treated oxidative stress in Wistar albino rats. CCl₄ injection induced oxidative stress by a significant rise in serum marker enzymes and thiobarbituric acid reactive substances (TBARS) along with the reduction of antioxidant enzymes. In serum, the activities of enzymes like ALP, ACP and protein and bilirubin were evaluated. Pretreatment of rats with different doses of plant extract (100 and 200 mg/kg) significantly lowered SGOT, SGPT and TBARS levels against CCl₄ treated rats. Hepatic enzymes like SOD, CAT, GPx were significantly increased by treatment with plant extract, against CCl₄ treated rats. Histopathological examinations showed extensive liver injuries, characterized by extensive hepatocellular degeneration/necrosis, inflammatory cell infiltration, congestion, and sinusoidal dilatation. Oral administration of the leaf extract at a dose of 200 mg/kg body weight significantly reduced the toxic effects of CCl₄. The activity of leaf extract at the dose of 200 mg/kg was comparable to the standard drug, silymarin. Based on these results, it was observed that *C. sativum* extract protects liver from oxidative stress induced by CCl₄ and thus helps in evaluation of traditional claim on this plant.

© 2008 Elsevier Ltd. All rights reserved.

1. Introduction

Liver is the first organ to metabolise all foreign compounds and hence it is susceptible to almost as many different diseases. Some are rare but there are a few, including hepatitis, cirrhosis, alcohol-related disorders and liver cancer. A major cause of these disorders is due to exposure to different environmental pollutants and xenobiotics e.g., paracetamol, carbon tetrachloride, thioacetamide, alcohol, etc. These toxicants mainly damage liver by producing reactive oxygen species (ROS).

Reactive oxygen free radicals have been known to produce tissue injury through covalent binding and lipid peroxidation and have been shown to augment fibrosis as seen from increased collagen synthesis (Geesin et al., 1990). Scavenging of free radicals by antioxidants could reduce the fibrosis process in the tissues (Thresemma and Kuttan, 1996). Free radicals may also be a contributory factor in a progressive decline in the function of immune system (Pike and Chandra, 1995). Cooperative defense systems that protect the body from free radical damage include the antioxidant nutrients and enzymes. The antioxidant enzymes include superoxide dismutase (SOD), catalase (CAT) and glutathione peroxidase

(GPx). Their role as protective enzymes is well-known and has been investigated extensively with *in vivo* models.

Conventional or synthetic drugs used in the treatment of liver diseases are inadequate and can have serious adverse effects. So there is a worldwide trend to go back to traditional medicinal plants. Many natural products of herbal origin are in use for the treatment of liver ailments. Polyphenolic compounds are widely distributed in plants and known to be excellent antioxidants *in vitro* and have the capacity to scavenge free radicals and protect antioxidant defence (Venkateswaran et al., 1997; Latha et al., 1999; Mitra et al., 2000; Dhuley and Naik, 1997).

Several medicinal plants have been screened based on the integrative approaches on drug development from Ayurveda (Mukerjee and Wahile, 2006). Since dietary polyphenol has been reported to be inversely associated with lipid peroxidation and cytotoxicity, an attempt was made to study the effects of the extracts of *Coriandrum sativum* on the activities of antioxidant enzymes in CCl₄ treated liver. *C. sativum* also called as “cilantro” is a well-known plant derived from the traditional system of medicine in India and a native of Mediterranean region. There are two distinct species with distinct morphological types. Only *C. sativum* L. is cultivated widely in the tropics. India has the prime position in the cultivation and production of Coriander (Sharma and Sharma, 2004). The seeds contain an essential oil “linalool” a monoterpenoid and the leaves contain good amount of caffeic acid, ferulic

* Corresponding author. Tel.: +91 9942689038.

E-mail address: sree_latha04@yahoo.com (S. Sreelatha).

acid, gallic acid and chlorogenic acid (Bajpai et al., 2005). The seeds and aerial parts of the plant are extensively used in traditional system of medicine for various ailments like spasm (Kurian, 2003) rheumatism, neuralgia, gastric complaints (Khare, 2004) bronchitis, diarrhoea, dysentery, gout, dyspepsia and giddiness. The plant is known to possess hypoglycemic (Chithra and Leelamma, 2000) antibacterial, antifungal (Fujita, 2004) free radical scavenging and lipid peroxidation activities (Tanabe et al., 2002). *C. sativum* was used as herbal constituent in the polyherbal formulation LIV-O-G which has been claimed to improve the liver dysfunction (Naidu et al., 2007). Quercetin 3-glucuronide, isoquercitrin and rutin were separated and identified in coriander fruits by means of chromatography on cellulose columns (Kunzemann & Herrmann, 1977). But no detailed investigations were carried out on the antioxidant effect of coriander leaf extracts. Since coriander leaves are one of the commonly used spices, we have made an attempt to evaluate the hepatoprotective effect of the leaves on oxidative damage induced by CCl₄ in rat hepatocytes.

2. Materials and methods

2.1. Plant material

The fresh leaves and stem of *C. sativum* were collected from the Horticultural research institute, Coimbatore, Tamilnadu region, India and authenticated through Botanical survey of India, Coimbatore, Tamilnadu, India. A voucher specimen has been deposited at the Herbarium unit. The plant samples were air-dried for 10 days and powdered. The powdered samples were placed in air tight container for future use.

2.2. Extraction

The air-dried leaves of *C. sativum* were made into a coarse powder. Two hundred and fifty grams of the powder was extracted with mixture of ethanol: water (7:3). The solvent was completely removed by rotary vacuum evaporator. The extract was freeze dried and stored in a vacuum desiccator for further use. The yield of the extract was 25% with reference to dry starting material.

2.3. Animals

Wistar albino rats (180–230 g) of either sex, procured from Tamilnadu University of Veterinary and Animal Sciences (TANUVAS) were used for the study. The animals were housed in large polypropylene cages in a temperature-controlled room (22 ± 2 °C) and provided with standardized pelleted feed (TANUVAS) and clean drinking water ad libitum. The study has got the clearance from the Institutional Animal Ethical Committee (IAEC) the Committee for the Purpose of Control and Supervision of Experiments on Animals (CPCSEA).

2.4. Phytochemical analysis

The leaves were subjected to preliminary phytochemical screening to identify the presence of various phytoconstituents present in the extract (Kokate et al., 1997) Precoated TLC plate of silicagel 60F₂₅₄ (E. Merck, India) of 0.2 mm thickness was used. Twenty microliters of the extract was spotted in the form of a band using Linomat IV Automatic spotter. TLC pattern was developed using toluene:acetone (5:1) as solvent system and visualised using vanillin sulphuric acid reagent. The R_f values and the percentage of separated compounds were determined.

2.5. Behavioural and toxic effects

Different groups of mice were treated with graded doses of the *C. sativum* extract (100 mg, 200 mg, 500 mg and 750 mg/kg, p.o). One group was maintained as control and was given 0.5% Tween-80. They were observed continuously for 1 h for any gross behavioural changes and death, if any and then, intermittently for the next 6h, and then again at 24 h after dosing with *C. sativum* extract.

2.6. Experimental procedure

Carbon tetrachloride (CCl₄) is a powerful hepatotoxin which is used extensively to generate experiments to study necrosis and steatosis of the liver in the rat (Perez-Tamayo, 1983; Wensing et al., 1990). Albino rats 4–6 weeks, 180–230 g were divided into six groups of six animals each. CCl₄ (1 ml/kg body weight) was administered to all groups of animals by intraperitoneal injection which is well documented to induce acute hepatotoxicity in rats (Wong et al., 2003). Group I served as control group, receiving normal saline only (10 ml/kg

i.p.). Group II served as CCl₄ control and received CCl₄:olive oil (1:1) on the 15th day. Group III and Group IV received the *C. sativum* stem extract that were given in two divided doses 100 mg/kg and 200 mg/kg respectively. Group V and Group VI received the *C. sativum* leaf extract that were given in two divided doses 100 mg/kg and 200 mg/kg, respectively, and the reference drug silymarin (25 ml/kg i.p.) was administered to Group VII, respectively, daily once for 15 days after CCl₄ administration. All the animals were killed at the end of 15th day after CCl₄ administration, blood was drawn from the carotid artery and serum was separated for the different assays.

2.7. Preparation of serum from blood

After 24 h, animals were sacrificed at the end of 15th day after CCl₄ administration, by chloroform anaesthesia. Blood was drawn from the carotid artery and serum was separated. Serum was separated by centrifugation at 600g for 15 min and analyzed for various biochemical parameters. The sera were stored in the –80 °C freezer before they were analyzed. Enzyme activities of aspartate aminotransferase (AST) and alanine aminotransferase (ALT) in blood serum were evaluated by an autoanalyzer (Shimadzu CL-7200, Shimadzu, Japan). After bleeding, complete gross postmortem examinations were performed on all terminated rats. The absolute and relative (organ-to-body weight ratio) weights of the liver were also measured for all rats when they were sacrificed.

2.8. Preparation of liver homogenate

Hepatic tissues were homogenized in KCL [10 mM] phosphate buffer (1.15%) with ethylene-diamine tetra acetic acid (EDTA: pH 7.4) and centrifuged at 12,000g for 60 min. The supernatant was used for the measurement of malondialdehyde (MDA), catalase (CAT), superoxide dismutase (SOD), and glutathione peroxidase (GPx). Total protein contents were determined by the method of Lowry et al. (1951), using bovine serum albumin as a standard. Activities of glutamate oxaloacetate transaminase (GOT), glutamate pyruvate transaminase (GPT), alkaline phosphatase (ALP) and acid phosphatase (ACP) were determined using commercial kit.

2.9. Determination of lipid peroxidation

Lipid peroxidation was measured by the thiobarbituric acid (TBA) reaction method (Berton et al., 1998). In brief, samples were mixed with TBA reagent consisting of 0.375% TBA and 15% trichloroacetic acid in 0.25-N hydrochloric acid. The reaction mixtures were placed in a boiling water bath for 30 min and centrifuged at 1811g for 5 min. The absorbance of the supernatant was measured at 535 nm. MDA, a measure of lipid peroxidation, was calculated using an extinction coefficient of 1.56 × 10⁵/M cm. The results were expressed as μM/mg protein.

2.10. Determination of antioxidant enzymes

Catalase activity was measured according to the method of Aebi (1984). One unit of catalase was defined as the amount of enzyme required to decompose 1 μM of H₂O₂ in 1 min. The reaction was initiated by the addition of 1.0 ml of freshly prepared 20 mM H₂O₂. The rate of decomposition of H₂O₂ was measured spectrophotometrically at 240 nm for 1 min. The enzyme activity was expressed as U/mg protein.

The activity of SOD was measured according to the method of McCord (1994). For the determination of SOD activity, xanthine and xanthine oxidase were used to generate superoxide radicals reacting with 2-(4-iodophenyl)-3-(4-nitrophenol)-5-phenyl tetrazolium chloride to form a red formazan dye. SOD activity was then measured at 505 nm.

GPx activity was determined by the method described by Pagila and Valentine (1967) and modified by Wendel (1981). The reaction mixture consisted of 400 μL, 0.25 M potassium phosphate buffer (pH 7.0), 200 μL supernatant, 100 μL GSH (10 mM), 100 μL NADPH (2.5 mM) and 100 μL glutathione reductase (6 U/mL). Reaction was started by adding 100 μL hydrogen peroxide (12 mM) and absorbance measured at 366 nm at 1 min intervals for 5 min using a molar extinction coefficient of 6.22 × 10³ M⁻¹ cm⁻¹. Data were expressed as U/mg of protein.

2.11. Histopathology

After the experimental period animals were decapitated, liver removed immediately, sliced and washed in saline. Liver pieces were preserved in 10% formalin for histopathological studies. The pieces of liver were processed and embedded in paraffin wax. Sections were taken and stained with hematoxylin and eosin and photographed (Coskun et al., 2000).

2.12. Statistics

All the values are represented as mean ± SE (n = 6). The statistical differences among different groups were analyzed by student's T-test. The difference showing a p level of 0.05 or lower was considered to be statistically significant.

3. Results

3.1. Phytochemical constituents and toxicity studies

The extract revealed the presence of various phytoconstituents like reducing and non-reducing sugars, polyphenolics, alkaloids, saponins and terpenoids. In acute toxicity, no mortality was observed up to a dose level of 750 mg/kg body weight.

3.2. Effect of *C. sativum* on CCl₄-induced hepatotoxicity

The activities of various biochemical enzymes in normal, CCl₄ control and treated groups were represented in Tables 1 and 2. The activities of ALT, AST, ALP, ACP and total bilirubin were significantly ($p < 0.001$) increased with a significant decrease in total protein levels in CCl₄ control compared to normal control. The levels of the above enzymes were significantly reversed on treatment with *C. sativum* in a dose-dependent manner. The activity of the leaf extract at the dose of 200 mg/kg was comparable to that of the reference drug silymarin.

3.3. Hepatic antioxidant enzyme activities

SOD, CAT and GPx were measured as an index of antioxidant status of tissues. Significantly lower liver SOD, catalase, and GSH-Px activity were observed in mice from the CCl₄ treated group as compared to the normal control group. There was a significant increase ($p < 0.05$) of SOD, CAT and GPx activity in the groups at a dose of 100 and 200 mg/kg, respectively, as compared to the CCl₄ treated group. Treatment with CCl₄ significantly decreased the SOD, CAT and GPx levels in the liver (47.84 ± 0.50 , 169.73 ± 5 ,

Table 1
Effects of *Coriandrum sativum* on CCl₄-induced hepatotoxicity.

Groups	AST(IU/L)	ALT(IU/L)	ALP(IU/L)
Control	96.5 ± 2.8	36.28 ± 1.5	15.92 ± 0.72
CCl ₄ (1 ml/kg i.p.)	185.3 ± 14.2	135.2 ± 12.4	98.5 ± 7.2
<i>Coriandrum sativum</i> stem extract (100 mg/kg)	165.6 ± 14.2 ^a	93.5 ± 8.4 ^a	78.1 ± 7.2 ^a
<i>Coriandrum sativum</i> stem extract (200 mg/kg)	125.8 ± 10.6 ^b	62.7 ± 5.8 ^b	52.4 ± 4.6 ^b
<i>Coriandrum sativum</i> leaf extract (100 mg/kg)	149.8 ± 12.5 ^a	84.6 ± 7.4 ^a	68.3 ± 5.3 ^a
<i>Coriandrum sativum</i> leaf extract (200 mg/kg)	104.5 ± 9.3 ^b	54.7 ± 4.3 ^b	46.6 ± 3.9 ^b
Silymarin (25 mg/kg)	103.6 ± 5.3 ^b	48.2 ± 4.1 ^b	34.8 ± 2.9 ^b

Values are expressed as mean ± SE, $n = 6$.

^a $p < 0.01$ vs. control.

^b $p < 0.001$ vs. control.

Table 2
Effects of *Coriandrum sativum* on the levels of ACP and bilirubin.

Groups	ACP (IU/L)	Bilirubin (mg/dl)	Protein (g/dl)
Control	10.8 ± 0.65	1.39 ± 0.04	5.21 ± 0.02
CCl ₄ (1 ml/kg i.p.)	39.2 ± 2.5	1.90 ± 0.29	4.52 ± 0.13
<i>Coriandrum sativum</i> stem extract (100 mg/kg)	30.4 ± 2.7 ^a	1.72 ± 0.25	5.43 ± 0.12 ^a
<i>Coriandrum sativum</i> stem extract (200 mg/kg)	22.7 ± 0.21 ^a	1.54 ± 0.32 ^a	5.32 ± 0.17 ^a
<i>Coriandrum sativum</i> leaf extract (100 mg/kg)	28.9 ± 0.47 ^a	1.65 ± 0.17	5.28 ± 0.07 ^a
<i>Coriandrum sativum</i> leaf extract (200 mg/kg)	18.6 ± 1.3 ^a	1.33 ± 0.24 ^a	5.15 ± 0.07 ^a
Silymarin (25 mg/kg)	16.2 ± 1.2 ^a	1.25 ± 0.03 ^a	5.16 ± 0.01 ^a

Values are expressed as mean ± SE, $n = 6$.

^a $p < 0.01$ vs. control.

Table 3
Effects of *Coriandrum sativum* on antioxidant enzymes.

Groups	Superoxide dismutase (mg liver protein)	Catalase (mg liver protein)	Glutathione peroxidase (mg liver protein)
Control	75.81 ± 1.94	296.83 ± 10.05	0.992 ± 0.05
CCl ₄ (1 ml/kg i.p.)	47.84 ± 0.50	169.73 ± 5.7	0.61 ± 0.03
<i>Coriandrum sativum</i> stem extract (100 mg/kg)	58.16 ± 0.72 ^a	234.16 ± 19.25 ^a	0.72 ± 0.16 ^a
<i>Coriandrum sativum</i> stem extract (200 mg/kg)	79.93 ± 0.65 ^a	252.27 ± 20.52 ^a	0.86 ± 0.12 ^a
<i>Coriandrum sativum</i> leaf extract (100 mg/kg)	63.51 ± 0.58 ^a	248.73 ± 22.16 ^a	0.84 ± 0.23 ^a
<i>Coriandrum sativum</i> leaf extract (200 mg/kg)	86.19 ± 0.72 ^a	264.79 ± 23.64 ^a	0.96 ± 0.45
Silymarin (25 mg/kg)	88.34 ± 2.54 ^a	268.27 ± 6.46 ^a	0.95 ± 0.03 ^a

Values are expressed as Mean ± SE, $n = 6$.

^a $p < 0.01$ vs. control.

0.61 ± 0.03 mg/protein) as compared to the normal control group (75.81 ± 1.94 , 296.83 ± 10.05 , 0.992 ± 0.05 mg/protein). By contrast, administration with *C. sativum* and silymarin significantly increased the levels as compared to the CCl₄-treated group. The levels were similar at animals treated with silymarin and those treated with leaf extract of *C. sativum* at dose of 200 mg/kg (Table 3).

3.4. Lipid peroxidation

MDA level is widely used as a marker of free radical mediated lipid peroxidation injury. We measured MDA levels in the liver and the results are shown in Table 4. MDA levels in the CCl₄ treated group (2.79 ± 0.14 nmol/mg protein) were significantly higher than that in the control group (1.29 ± 0.39 nmol/mg protein, $p < 0.05$). MDA levels in the leaf extract treated group of *C. sativum* (1.46 ± 0.41 and 1.29 ± 0.4 nmol/mg protein at dose of 100 and 200 mg/kg, respectively) were significantly lower than that in the CCl₄ treated group ($p < 0.05$). Silymarin also inhibited the elevating MDA levels upon CCl₄ administration. These findings indicated that the free radicals being released in the liver were effectively scavenged when treated with the leaf and stem extracts of *C. sativum*.

3.5. Histopathology

The histopathological studies of the liver showed (Plates 1 and 2) fatty changes, swelling and necrosis with loss of hepatocytes in CCl₄ control rats in comparison with normal control. The stem and leaf extract treated groups of *C. sativum* showed regeneration of hepatocytes, normalization of fatty changes and necrosis of the liver. The silymarin treated group showed almost normalization of

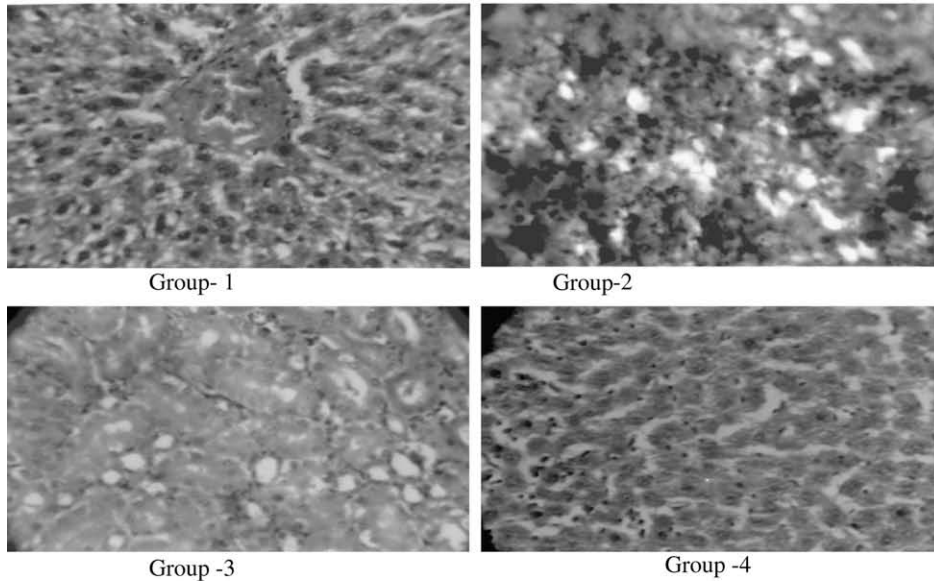
Table 4
Effects of *Coriandrum sativum* on the level of TBARS.

Groups	TBARS (nmol MDA/mg protein)
Control	1.29 ± 0.395
CCl ₄ (1 ml/kg i.p.)	1.79 ± 0.14
<i>Coriandrum sativum</i> stem extract (100 mg/kg)	1.52 ± 0.21
<i>Coriandrum sativum</i> stem extract (200 mg/kg)	1.43 ± 0.23 ^a
<i>Coriandrum sativum</i> leaf extract (100 mg/kg)	1.46 ± 0.41 ^a
<i>Coriandrum sativum</i> leaf extract (200 mg/kg)	1.29 ± 0.4 ^a
Silymarin (25 mg/kg)	1.26 ± 0.14 ^a

Values are expressed as Mean ± SE, $n = 6$.

^a $p < 0.01$ vs. control.

PLATE 1
HISTOPATHOLOGICAL ARCHITECTURE IN THE LIVER
OF CONTROL AND EXPERIMENTAL RATS
(H&E 100x)



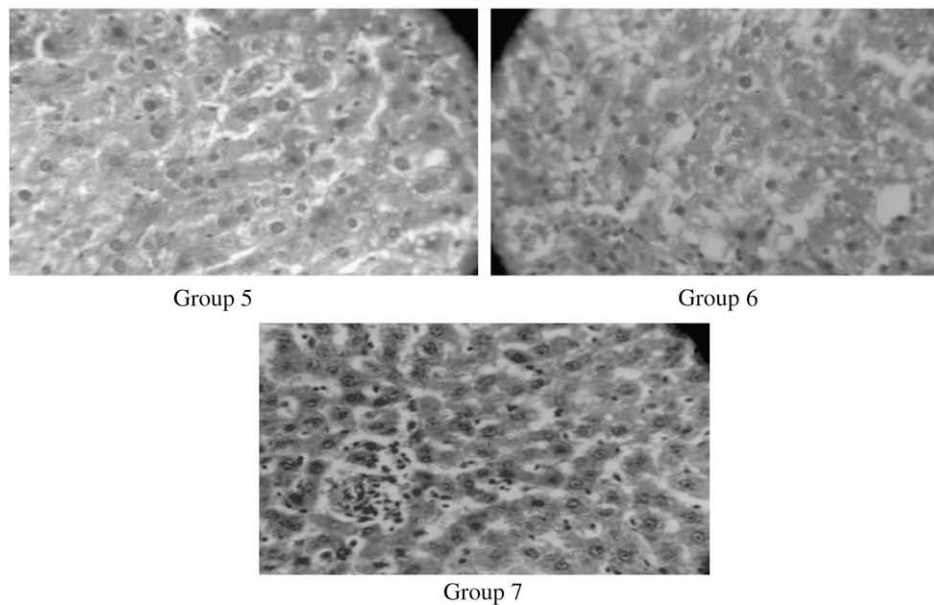
Group 1-Normal liver

Group 2-CCl₄ treated

Group 3-CCl₄+*Coriandrum sativum* Leaf extract (100mg/kg)

Group 4-CCl₄+*Coriandrum sativum* Leaf extract (200mg/kg).

Plate 2



Group 5-CCL₄+*Coriandrum sativum* Stem extract (100mg/kg).

Group 6-CCL₄+*Coriandrum sativum* Stem extract (200mg/kg).

Group 7-Silymarin (25mg/kg).

Fig. 1. Histopathology of liver tissues (1) section shows central vein surrounded by hepatic cord of cells (normal architecture), (2) shows patches of liver cell necrosis with inflammatory collections, around central vein and focal necrosis with sinusoidal dilatation (CCl₄) (3 and 4) less inflammatory cells around central vein, absence of necrosis (5 and 6) less inflammation around dilated central vein, (7) minimal inflammatory cellular infiltration.

fatty accumulation and necrosis. The maximum protection against hepatic damage was achieved with the leaf extract at dose of 200 mg/kg (see Fig. 1).

4. Discussion

The present study reports the potential hepatoprotective activity of *C. sativum* against hepatic injury produced by carbontetrachloride in rats. CCl₄ is a well-known hepatotoxic agent and the preventive action of liver damage by CCl₄ has been widely used as an indicator of liver protective activity of drugs in general. The changes associated with CCl₄-induced liver damage are similar to that of acute viral hepatitis. It is metabolized in the liver to excretable glucuronide and sulphide conjugates (Jollow et al., 1974). An obvious sign of hepatic injury is the leaking of cellular enzymes into the plasma (Schmit et al., 1975) due to the disturbance caused in the transport function of hepatocytes (Zimmerman and Seeff, 1970). When liver cell plasma is damaged a variety of enzymes located normally in cytosol is released into the blood, thereby causing increased enzyme level in the serum. The estimation of enzymes in the serum is a useful quantitative marker of the extent and types of hepatocellular damage (Jadon et al., 2007).

In the present investigation, the dose of CCl₄ used, caused liver injury in rats. The rats treated with an overdose of CCl₄ developed significant hepatic damage, which was observed through a substantial increase in the concentration of serum parameters. Pre treatment of the rats with *C. sativum* extract at 100 and 200 mg/kg for 15 days before CCl₄ administration resulted in a significant protection of CCl₄-induced by the elevation of serum marker enzymes. *C. sativum* appears to be effective in reducing the injurious effect of CCl₄, observed in the study. This was an indication of stabilization of plasma membrane, as well as repair of hepatic tissue damage, caused by CCl₄. The results are in agreement with the commonly accepted view that serum level of transaminase returns to normal with healing of hepatic parenchyma and the regeneration of hepatocytes. Further, the stimulation of hepatic regeneration was known to make the liver more resistant to damage by toxins (Thabrew et al., 1987).

In the present study pretreatment with *C. sativum* showed increased activity of antioxidant enzymes compared to CCl₄ treated animals indicating the potentiality of *C. sativum* to act as an antioxidant by preventing the peroxidative damage caused by CCl₄. Total Protein is done as a routine test to evaluate the toxicological nature of various chemicals (Nevin and Vijayammal, 2005). The decreased total protein in CCl₄ treated groups is due the damage caused to the liver by CCl₄. The ability of *C. sativum* to maintain the total protein may be due to the non-toxic antioxidant constituents present in the extract.

Hepatic cells participate in a variety of metabolic activities and contain a host of enzymes. In tissues, Aspartate amino transferase (AST) and Alanine amino transferase (ALT) are found in higher concentrations in cytoplasm and AST in particular also exists in mitochondria. In liver injury, the transport function of the hepatocytes is disturbed, resulting in the leakage of plasma membrane, thereby causing an increased enzyme level in serum, and soluble enzymes like AST will also be similarly released. The elevated activities of AST and ALT in serum are indicative of cellular leakage and loss of functional integrity of cell membranes in liver (Rajesh and Latha, 2004). Administration of CCl₄ significantly raised the serum level of enzymes like AST and ALT in rats as observed in our result. Oral administration of *C. sativum* at a dose of 200 mg/kg body weight to rats caused a decrease in the activity of the above enzymes, which may be a consequence of the stabilization of plasma membrane as well as repair of hepatic tissue damage caused by CCl₄. This is supported by the view that serum levels of transaminases

return to normal with the healing of hepatic parenchyma and regeneration of hepatocytes (Thabrew et al., 1987). SGOT is found in the liver, cardiac muscles, skeletal muscles, pancreas, lungs, kidney, brain, etc., where as SGPT concentration is highest in the liver and therefore, it appears to be more sensitive test for hepatocellular damage than SGOT (Lin et al., 1997).

Leakage of large quantities of enzymes into the blood stream is often associated with massive necrosis of the liver (Shyamal et al., 2006). CCl₄ is known to cause marked elevation in serum enzymes (SGOT and SGPT). In the present study, a significant increase in the activities of SGOT and SGPT on exposure to CCl₄ was observed, indicating considerable hepatocellular injury. Our results indicated that *C. sativum* (200 mg/kg) administration significantly alleviated the increased serum enzymes induced by CCl₄, indicating improvement of the functional status of the liver, which was also supported by the histopathological findings.

The activity of serum alkaline phosphatase was also elevated during CCl₄ administration. Alkaline phosphatase is excreted normally via bile by the liver. In liver injury due to hepatotoxin, there is a defective excretion of bile by the liver which is reflected in their increased levels in serum. Hyperbilirubinaemia is a very sensitive test to substantiate the functional integrity of the liver and severity of necrosis which increases the binding, conjugation and excretory capacity of hepatocytes that is proportional to the erythrocyte degeneration rate (Singh et al., 1998). Depletion of elevated bilirubin level together with the suppression of activity of ALP in serum of rats treated with *C. sativum*, suggest to stabilize biliary dysfunction of rat liver during chronic injury with CCl₄.

Reactive oxygen species (ROS), such as superoxide anions and H₂O₂, are produced throughout cells during normal aerobic metabolism. The intracellular concentration of ROS is a consequence of both their production and their removal by various antioxidants. A major component of the antioxidant system in mammalian cells consists of three enzymes, namely, superoxide dismutase (SOD), catalase (CAT) and glutathione peroxidase (GPx). These enzymes work in concert to detoxify superoxide anion and H₂O₂ in cells. Our results indicated that pretreatment of *C. sativum* caused an increase in the activity of antioxidant enzymes. Recent studies on the antioxidant properties of flavonoids from various plant extracts reveal their stimulatory action on antioxidative enzymes (Nagata et al., 1999).

Some flavonoids exert a stimulatory action on transcription and gene expression of certain antioxidant enzymes (Rohrdanz et al., 2002). The antioxidant enzyme system plays an important role in the defence of cells against oxidative insults. The study examined the ameliorating effect of the extracts from *C. sativum*, on oxidative stress induced by CCl₄. The levels of glutathione and TBARS approached the normal control in all *C. sativum*-treated animals exposed to CCl₄. Restoration of TBARS to nearly normal levels by these extracts may be due to an enhancement of antioxidant enzymes, such as superoxide dismutase, catalase, glutathione peroxidase, glutathione reductase and glutathione-S-transferase. In the present study, CCl₄ treatment significantly decreased the activity of antioxidant enzymes. Our result is in agreement with several reports.

Most of the hepatotoxic chemicals including CCl₄ damaged liver mainly by inducing lipid peroxidation directly or indirectly. In higher animals peroxy radicals are important agents that mediate lipid peroxidation thereby damaging cell membrane, leading to liver injury, arteriosclerosis and kidney damage (Recknagel et al., 1989). In the present study, *C. sativum* extract was effective in reducing the production of TBARS. They reported the strongest inhibition of malondialdehyde (MDA), MDA is a major reactive aldehyde that appears during the peroxidation of biological membrane polyunsaturated fatty acid (Vaca et al., 1988). Therefore, the hepatic content of MDA is used as an indicator of liver tissue damage involving a series of chain reactions (Ohkawa et al., 1979).

It has been accepted that lipid peroxidation of hepatocyte membranes is one of the principal causes of CCl₄-induced hepatotoxicity, and is mediated by the production of free radical derivatives of CCl₄ (Recknagel et al., 1989; Basu, 2003 and Weber et al., 2003). In the present study, a single dose of CCl₄ at 1 ml/kg resulted in a significant increase in the hepatic MDA concentration, indicating increased lipid peroxidation caused by administration of CCl₄. Highly significant activities of superoxide dismutase and catalase were correlated with the reduction of lipid peroxides. The significant dose-dependent decrease in the hepatic MDA concentration confirms that pretreatment with *C. sativum* extracts could effectively protect against the hepatic lipid peroxidation induced by CCl₄.

The histological observations basically supported the results obtained from serum enzyme assays. The liver of CCl₄ intoxicated rats showed massive fatty changes gross necrosis, broad infiltration of lymphocyte and kupffer cells around the central vein and loss of cellular boundaries. The histopathological observations of the liver of rats pretreated with *C. sativum* and subsequently given CCl₄ showed a more or less normal architecture of the liver having reversed to a large extent, the hepatic lesions produced by the toxins, almost comparable to the normal control and silymarin groups. It is suggested that *C. sativum* acts by its stabilizing effect on the plasma membrane as was reported in case of silymarin. The stimulation of hepatic regeneration makes the liver more resistant to damage by the toxin (Sadasivan et al., 2006). *C. sativum* inhibited liver lipid peroxidation and resultant tissue degeneration, thus acting as an effective antioxidant.

In conclusion, it may be mentioned that the altered biochemical profiles due to CCl₄ exposure is reversed towards normalization by *C. sativum* extract but the effect was more pronounced with the leaf extract. The contents of the extract not only protect the integrity of plasma membrane but, at the same time increased the regenerative and reparative capacity of the liver. Beneficial effect of the *C. sativum* extract may be due to the presence of some phenolic components that have membrane stabilizing effects. These results suggests that the compound present in the plant extract efficiently works on the liver to keep it normally functioning and minimizing cell membrane disturbances.

Conflict of interest statement

The authors declare that there are no conflicts of interest.

Acknowledgements

The authors are grateful to Dr. Jaswanth from Periyar college, Trichy for his interest on the subject, precious advices and helpful discussions.

References

- Aebi, H., 1984. Catalase *in vitro*. In: Packer, L. (Ed.), *Methods in Enzymology*, vol. 105. Academic Press, San Diego, pp. 121–126.
- Basu, S., 2003. Carbon tetrachloride-induced lipid peroxidation: eicosanoid formation and their regulation by antioxidant nutrients. *Toxicology* 189, 113–127.
- Berton, T.R., Conti, C.J., Mitchell, D.L., Aldaz, C.M., Lubet, R.A., Fischer, S.M., 1998. The effect of vitamin E acetate on ultraviolet-induced mouse skin carcinogenesis. *Mol. Carcinogen.* 23, 175–184.
- Bajpai, M., Mishra, A., Prakash, D., 2005. Antioxidant and free radical scavenging activities of some leafy vegetables. *Int. J. Food Sci. Nutr.* 56, 73–81.
- Chithra, V., Leelamma, S., 2000. *Coriandrum sativum* – effect on lipid metabolism in 1,2-dimethyl hydrazine induced colon cancer. *J. Ethnopharm.* 71, 457–463.
- Coskun, O., Yakan, B., Oztas, E., Sezen, A., 2000. Antioxidant and hepatoprotective activity of vitamin E and EGb 761 in experimental endotoxemic rats. *Turk. J. Med. Sci.* 30, 27–29.
- Dhuley, J.N., Naik, S.R., 1997. Protective effect of Rhinax, a herbal formulation against CCl₄-induced liver injury and survival in rats. *J. Ethnopharm.* 56, 159–164.
- Fujita, K., 2004. Antioxidant activity of coriander volatile compounds against salmonella choleraeae. *J. Agri. Food Chem.* 4, 3329–3332.
- Geesin, J.C., Gordon, J.S., Bergand, R.A., 1990. Retinoids affect collagen synthesis through inhibition of ascorbate-induced lipid peroxidation in cultured human dermal fibroblasts. *Arch. Biochem. Biophys.* 278, 350–355.
- Jadon, A., Bhadauria, M., Shukla, S., 2007. Protective effect of *Terminalia bellerica* Roxb. and gallic acid against carbon tetrachloride induced damage in albino rats. *J. Ethnopharm.* 109, 214–218.
- Jollow, D.J., Thorgeirsson, S.S., Potter, W.Z., Hashimoto, M., Mitchell, J.R., 1974. Acetaminophen-induced hepatic necrosis. IV Metabolic disposition of toxic and non-toxic doses of acetaminophen. *Pharmacology* 12, 251–271.
- Khare, C.P., 2004. Antioxidant and Phytochemicals on Herbs. *Encyclopedia of Indian Medicinal Plants*, vol. 9. pp. 162–167.
- Kokate, C.K., Purohit, A.P., Gokhale, S.B., 1997. Analytical pharmacognosy: phytochemical investigations. In: Prakashan, N. (Ed.), *Pharmacognosy*, fifth ed. Nirali Prakashan, India, pp. 119–137.
- Kunzemann, J., Herrmann, K., 1977. Isolation and identification of flavon(ol)-O-glycosides in caraway (*Carum carvi* L.), fennel (*Foeniculum vulgare* Mill.), anise (*Pimpinella anisum* L.), and coriander (*Coriandrum sativum* L.), and of flavon-C-glycosides in anise. I. Phenolics of spices. *Zeitschrift für Lebensmitteluntersuchung und forschung A* 164 (3), 194–200.
- Kurian, J.C., 2003. *Coriandrum sativum*, Plants that Heal, fifth ed. Oriental Watchman Publishing House, Pune, India, vol. 15. pp. 192–195.
- Latha, U., Rajesh, M.G., Latha, M.S., 1999. Hepatoprotective effect of an ayurvedic medicine. *Indian Drug.* 36, 470–473.
- Lin, C.C., Shieh, D.C., Yen, M.H., 1997. Hepatoprotective effect of the fractions of *Ban-zhi-lian* on experiment liver injuries in rat. *J. Ethnopharm.* 56, 193–200.
- Lowry, O.H., Rosebrough, N.J., Farr, A.L., Randall, R.J., 1951. Protein measurement with folin phenol reagent. *J. Biol. Chem.* 193, 265–275.
- McCord, J.M., 1994. Mutant mice, Cu, Zn superoxide dismutase, and motor neuron degeneration. *Science* 266, 1586–1587.
- Mitra, S.K., Seshadri, S.J., Venkataranganna, M.V., Gopumadhavan, S., Venkatesh, U., Udupa, D.N., Sarma, K., 2000. Effect of HD-03-a herbal formulation in galactosamine-induced hepatopathy in rats. *Ind. J. Physiol. Pharm.* 44, 82–86.
- Mukerjee, P.K., Wahile, A., 2006. Integrated approaches towards drug development from ayurveda and other Indian system of medicines. *J. Ethnopharm.* 103, 25–35.
- Nagata, H., Takekoshi, S., Takagi, T., Honma, T., Watanabe, K., 1999. Antioxidative action of flavonoids, quercetin and catechin, mediated by the activation of glutathione peroxidase. *Tokai J. Expt. Clin. Med.* 24, 1–11.
- Nevin, K.G., Vijayammal, P.L., 2005. Effect of *Aerva lanata* on solid tumor induced by DLA cells in mice. *Fitoterapia* 74, 578–580.
- Naidu, S.R., Kumar, G.S., Gawade, P.S., Devi, K., 2007. Protective effect of LIV-O-G a polyherbal formulation on alcohol-CCl₄ and paracetamol induced hepatotoxicity in rats. *Pharmacologyonline* 3, 446–460.
- Ohkawa, H., Ohishi, N., Yagi, K., 1979. Assay of lipid peroxides in animal tissue by thiobarbituric acid reaction. *Anal. Biochem.* 95, 351–358.
- Pagila, D.E., Valentine, W.E., 1967. Study on quantitative and qualitative characterization of erythrocyte glutathione peroxidase. *J. Lab. Clin. Med.* 702, 158–162.
- Perez-Tamayo, R., 1983. Is cirrhosis of the liver experimentally produced by CCl₄ an adequate model of human cirrhosis? *Hepatology* 3, 112–120.
- Pike, J., Chandra, R.K., 1995. Effect of vitamin and trace element supplementation on immune indices in healthy elderly. *Int. J. Vit. Nutr. Res.* 65, 117–120.
- Rajesh, M.G., Latha, M.S., 2004. Protective effect of *Glycyrrhiza glabra* Linn. on carbon tetrachloride-induced peroxidative damage. *Ind. J. Pharmacol.* 36, 284–286.
- Recknagel, R.O., Glende, E.A., Dolak, J.A., Waller, R.L., 1989. Mechanisms of carbon tetrachloride toxicity. *Pharm. Thera.* 43, 139–154.
- Rohrdanz, E., Ohler, S., Tran-Thi, Q.H., Kahl, R., 2002. The phytoestrogen daidzein affects the antioxidant enzyme system of rat hepatoma H4IIE cells. *J. Nutr.* 132 (3), 370–375.
- Sadasivan, S., Latha, P.G., Sasikumar, J.M., Rajashekarana, S., Shymal, S., Shine, V.J., 2006. Hepatoprotective studies on *Hedyotis corymbosa* (L.) Lam. *J. Ethnopharm.* 106, 25–249.
- Schmit, E., Schmit, F.W., Otto, P., Vido, I., Wrogegan, K., Herfarth, C., 1975. Liver morphology and enzyme release. Further studies in the isolated per fused rat liver. In: *Pathogenesis and Mechanism of Liver Cell Necrosis*. Medical and Technical Publication, Lancaster, UK.
- Sharma, M.M., Sharma, R.K., 2004. Coriander. In: K.V. Peter (Ed.), *Handbook of Herbs & Spices*, vol. 2. CRC, Woodhead Publishing Limited, pp. 145–161.
- Shyamal, S., Latha, P.G., Shine, V.J., Sujja, S.R., Rajasekharan, S., Ganga Devi, T., 2006. Hepatoprotective effects of *Pitopsisporum neelgherrense*, a popular Indian ethnomedicine. *J. Ethnopharm.* 107, 151–155.
- Singh, B., Saxena, A.K., Chandan, B.K., Anand, K.K., Suri, O.P., SuriSatti, K.A., SuriSatti, N.K., 1998. Hepatoprotective activity of verbenalin on experimental liver damage in rodents. *Fitoterapia* 69, 134–140.
- Tanabe, H., Yoshida, M., Tomita, N., 2002. Comparison of the antioxidant activities of 22 commonly used herbs and spices on the lipid oxidation of pork meat. *Anim. Sci. J.* 73, 389–393.
- Thabrew, M.I., Joice, P.D., Rajatissa, W.A., 1987. Comparative study of efficacy of *Paetta indica* and *Osbeckia octandra* in the treatment of liver dysfunction. *Planta Med.* 53, 239–241.
- Thresiamma, K.C., Kuttan, R., 1996. Inhibition of liver fibrosis by ellagic acid. *Indian J. Physiol. Pharm.* 40, 363–366.

- Vaca, C.E., Wilhelm, J.M., Harms-Rihdsahl, M., 1988. Interaction of lipid peroxidation product with DNA. *Mutat. Res. Rev. Gen. Toxicol.* 195, 137–149.
- Venkateswaran, S., Pari, L., Viswanathan, P., Menon, V.P., 1997. Protective effects of Liver, a herbal formulation against erythromycin estolate-induced hepatotoxicity in rats. *J. Ethnopharm.* 57, 161–167.
- Weber, L.W.D., Bull, M., Stampfl, A., 2003. Hepatotoxicity and mechanism of action of haloalkanes: carbon tetrachloride as a toxicological model. *Crit. Rev. Toxicol.* 33, 105–136.
- Wendel, A., 1981. Gluthathione peroxidase. *Methods Enzymol.* 77, 325–333.
- Wensing, G., Sabra, R., Branch, R.A., 1990. Renal and systemic hemodynamics in experimental cirrhosis in rats—relation to hepatic function. *Hepatology* 12, 13–19.
- Wong, C.K., Ooi, V.E.C., Wong, C.K., 2003. Protective effects of N-acetylcysteine against carbon tetrachloride and trichloroethylene-induced poisoning in rats. *Environ. Toxicol. Pharm.* 14, 109–116.
- Zimmerman, H.J., Seeff, L.B., 1970. Enzymes in hepatic disease. In: Goodley, E.L. (Ed.), *Diagnostic Enzymology*. Lea and Febiger, Philadelphia, pp. 1–3.