Acute Reversible Diffuse Conduction System Disease due to Lyme Disease

DAVID A. RUBIN, CARMINE SORBERA, SETH BAUM, ANNEMARIE McALLISTER, and ROBERT NADELMAN

From the Division of Cardiology and Infectious Disease, Westchester County Medical Center, New York Medical College, Valhalla, New York

RUBIN, D.A., ET AL.: Acute Reversible Diffuse Conduction System Disease due to Lyme Disease. *During the acute phase of Lyme disease, a 56-year-old man without previous heart disease developed complete heart block with alternating left and right bundle branch block pattern QRS complexes. Electrophysiological study performed in the acute phase revealed marked HV prolongation, although the level of heart block was at the atrioventricular node. The heart block was mildly symptomatic and resolved (as did the bundle branch block) with antibiotic therapy. Lyme disease may cause reversible His-Purkinje disease. (PACE, Vol. 13, November, Part I 1990)*

heart block, Lyme disease

Introduction

Lyme disease, caused by *Borrelia burgdorferi* and transmitted by ixodid ticks, is a recognized cause of reversible atrioventricular block.[1] Based on Wenckebach periodicity with narrow QRS complexes on the surface electrocardiograms, most authors feel that the heart block is at the level of the atrioventricular node.[2–4] Concomitant infranodal disease would be difficult to ascertain without intracardiac electrophysiological study. Few electrophysiological studies and even fewer performed during the acute illness have been reported. We report a patient with diffuse (nodal and infranodal) reversible conduction system disease documented by intracardiac electrophysiological study performed during the acute phase of Lyme disease.

Case Report

A 56-year-old man without prior cardiac history presented to Lyme Disease Clinic with 3 weeks of fever, arthralgias, headache, episodic lightheadedness, and a fading abdominal rash consistent with erythema migrans-all occurring after a tick bite. His pulse was 45, and there were no signs of congestive heart failure. Admission electrocardiogram is shown in Figure 1 and demonstrates complete heart block with an escape rhythm of a wide left bundle branch block pattern. Monitoring revealed high degree atrioventricular block of both right bundle branch block and left bundle branch block QRS configuration. The ventricular rate was 40–48. An electrophysiologic study performed within 12 hours of admission revealed markedly prolonged AH and HV intervals with periods of high degree heart block. The level of block was supra-Hisian (Fig. 2). There were periods of junctional escape beats and periods of ventricular escape beats of similar rate but different morphology. Sinus node recovery time was normal. Incremental atrial pacing revealed the level of block to always be at the level of the atrioventricular node. There was no response to intravenous atropine. An echocardiogram was normal and ejection fraction by MUGA scan was 0.64. A presumptive diagnosis of Lyme disease with complicating complete heart block was confirmed by a positive Lyme titer of 178.8 (normal < 75) by the FIAX method (Whittaker

Address for reprints: David A. Rubin, M.D., Division of Cardiology, Westchester County Medical Center, Valhalla, NY 10595.

Received March 26, 1990; revision June 26, 1990; accepted August 16, 1990.

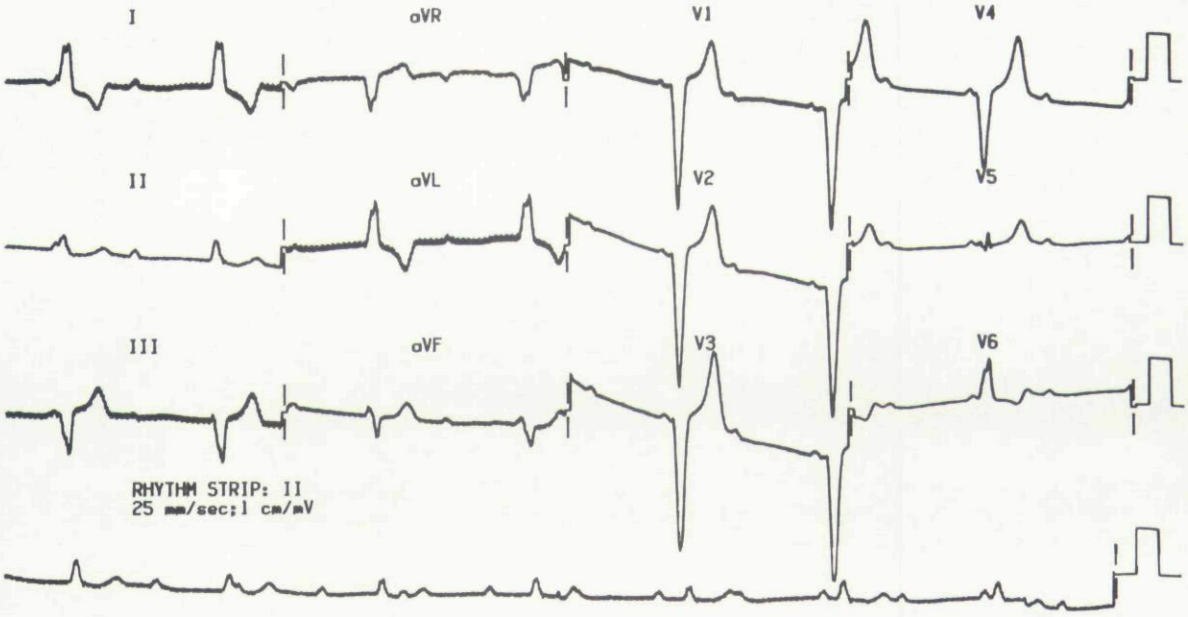

Figure 1. *Admission ECG shows complete heart block with a left bundle branch block QRS pattern.*

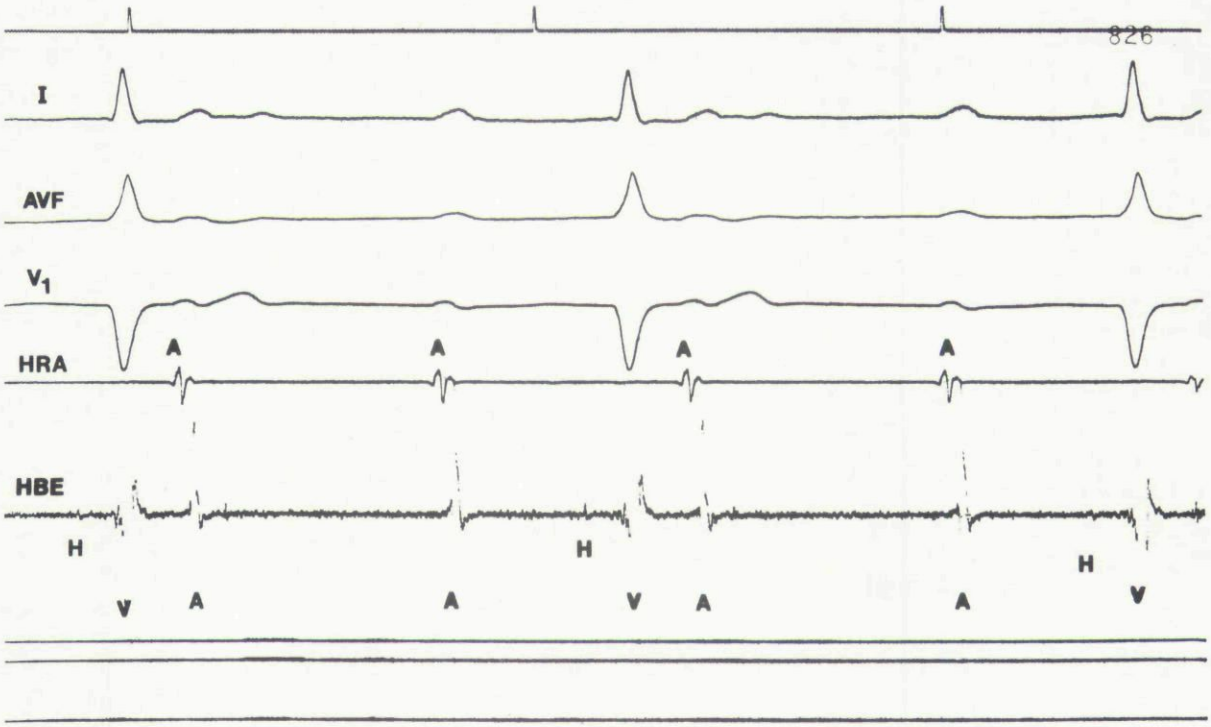

Figure 2. *His-bundle recording demonstrates 2:1 block at the level of the AV node. The AH interval of the conducted beat is markedly prolonged (320 ms). The HV interval is markedly prolonged −80 ms (normal < 55 ms) Surface leads are labelled and show a left bundle branch block QRS pattern. HBE = His-bundle catheter tracing; A = atrial electrogram; H = His-bundle electrogram; V = ventricular electrogram. Time lines (1000 ms) are at the top of the tracing.*

M.A. Bioproducts, Walkersville, MD, USA). He received 10 days of intravenous ceftriaxone followed by 11 days of oral doxycycline therapy. No steroids were administered. Seven days into therapy, he reverted to normal sinus rhythm and an electrocardiogram after 3 weeks of therapy showed only borderline first-degree heart block without bundle branch block (Fig. 3).

Discussion

Cardiac involvement occurs in 4%–8% of patients with Lyme disease. Carditis occurs following hematogenous spread, usually days to weeks after the initial infection.[1] The most common manifestation is atrioventricular block ranging from first degree to third degree.[2] Based on surface electrocardiographic characteristics of Wenckebach periodicity and normal QRS duration, the block has been ascribed to the level of the atrioventricular node.[1–4] There are a few confirmatory intracardiac electrophysiology studies in the English language literature. Steere[2] performed electrophysiological studies on two patients during their acute illness. Both had supra-Hisian block with normal HV intervals.[2] Reznick[3] reported one patient with supra-Hisian block, but did not report the HV interval.

Several patients with high degree atrioventricular block and a wide QRS complex have been reported.[2,4] These electrocardiographic findings have suggested more diffuse cardiac conduction system involvement. There is only one report of infranodal disease complicating Lyme disease in the English language literature. In this patient with resolving heart block, the HV interval obtained by a "pullback" of a temporary pacemaker introduced via the subclavian vein was moderately prolonged.[4] Our patient confirms that Lyme

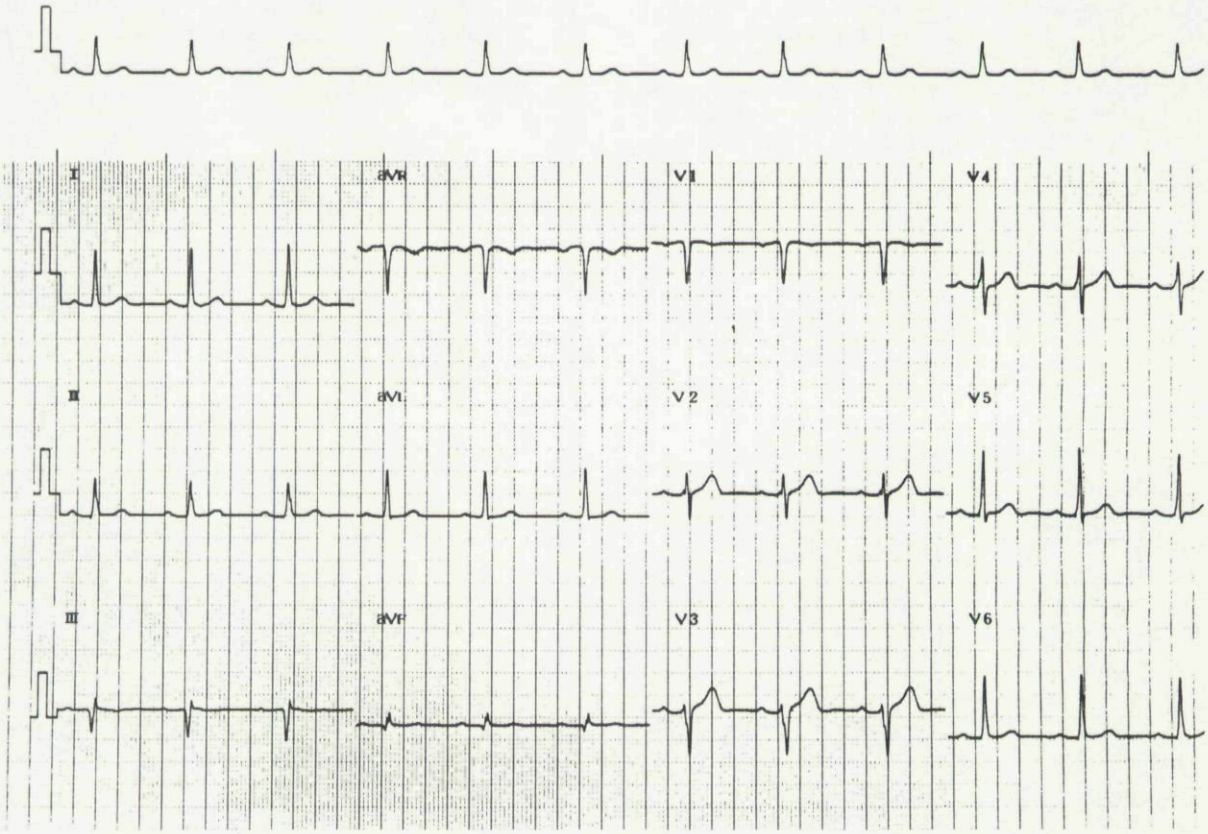

Figure 3. *ECG after 3 weeks of antibiotic therapy showing resolution of both the left bundle branch block and the high degree AV block.*

disease can cause diffuse conduction system disease. He had not only high degree atrioventricular block but alternating right bundle branch block and left bundle branch block suggesting infranodal dysfunction. This was documented by electrophysiological study. Although the level of high degree atrioventricular block was clearly at the level of the atrioventricular node, the HV interval was markedly prolonged.

The atrioventricular block and bilateral bundle branch block in our patient, as in previously reported cases, proved reversible with antibiotics and did not require either steroids or temporary pacing. Without a follow-up electrophysiological study, we cannot exclude mild residual atrioventricular node or His-Purkinje system impairment. Significant impairment, however, seems unlikely given the ECG resolution and the patient's clinical course. Thus, even in the presence of diffuse conduction system disease, antibiotics appear to be effective and permanent pacing may not be required. Although not required in our patient, temporary pacing may be required in patients with severe bradycardia or symptoms.

The mechanism of conduction system injury is not known. Recent reports have demonstrated the presence of organisms in myocardial tissue suggesting direct invasion as the possible etiology.[5,6]

References

1. Steere A. Lyme disease. N Engl J Med 1989; 321:586–596.
2. Steere A, Batsford WP, Weinberg M, et al. Lyme Carditis: Cardiac abnormalities of Lyme disease. Ann Intern Med 1980; 93:8–16.
3. Reznick J, Braunstein D, Walsh R, et al. Lyme carditis. Am J Med 1986; 81:923–927.
4. McAlister H, Klementowicz P, Andrews C, et al. Lyme carditis: An important cause of reversible heart block. Ann Intern Med 1989; 110:339–345.
5. deKoning J, Hoogkamp-Korstanje J, vanderLinde M, et al. Demonstration of spirochetes in cardiac biopsies of patients with Lyme disease. J Infect Dis 1989; 160:150–153.
6. Stanek G, Klein J, Bittner R, et al. Isolation of *Borrelia Burgdorferi* from the myocardium of a patient with long standing cardiomyopathy. N Engl J Med 1990; 322:249–252.